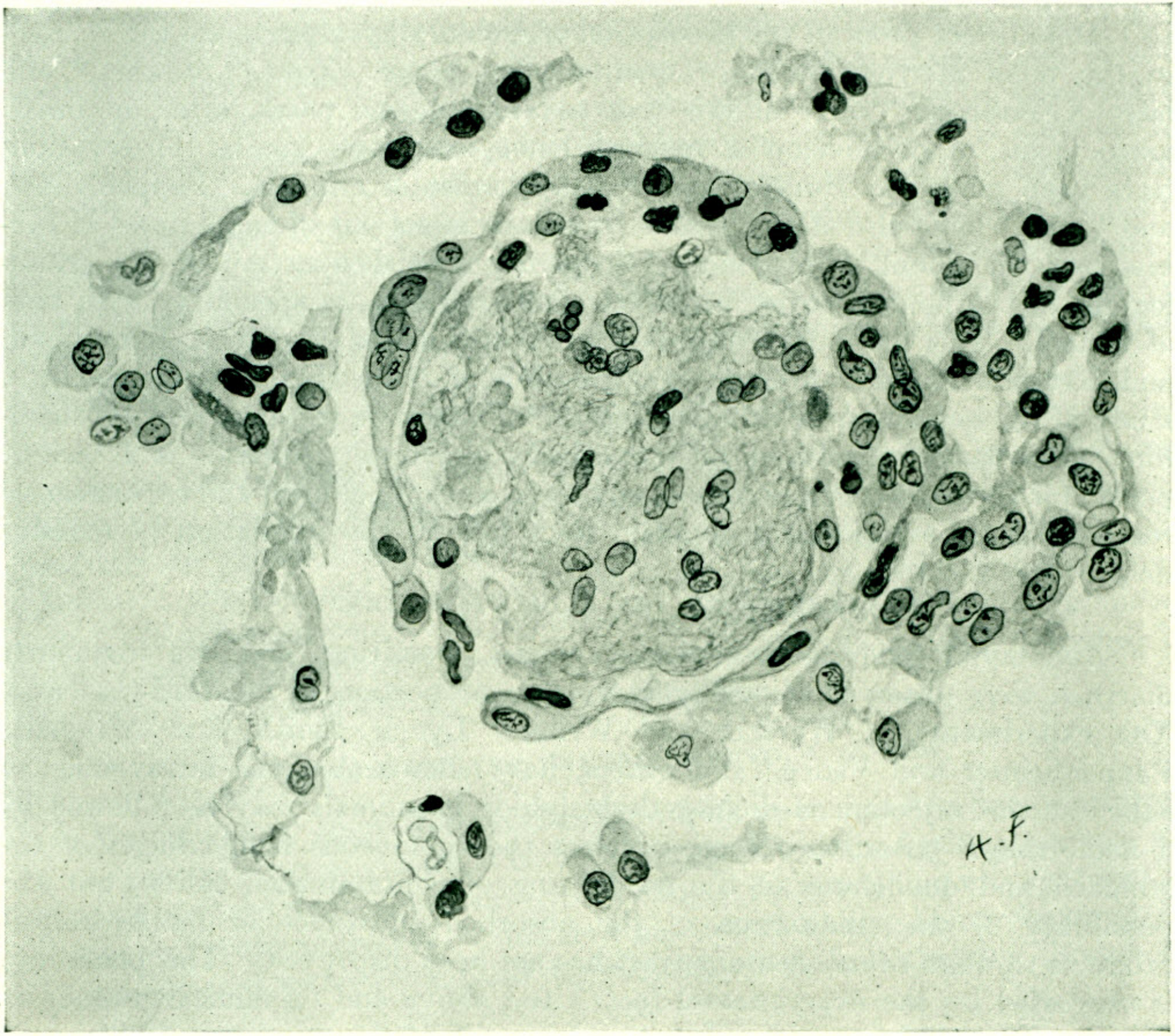

FIG. 26.—Case 74. Mustard-gas burn, 12 days' duration. Lung. Proliferation of alveolar epithelium over a mass of fibrin and agglomerated red blood corpuscles