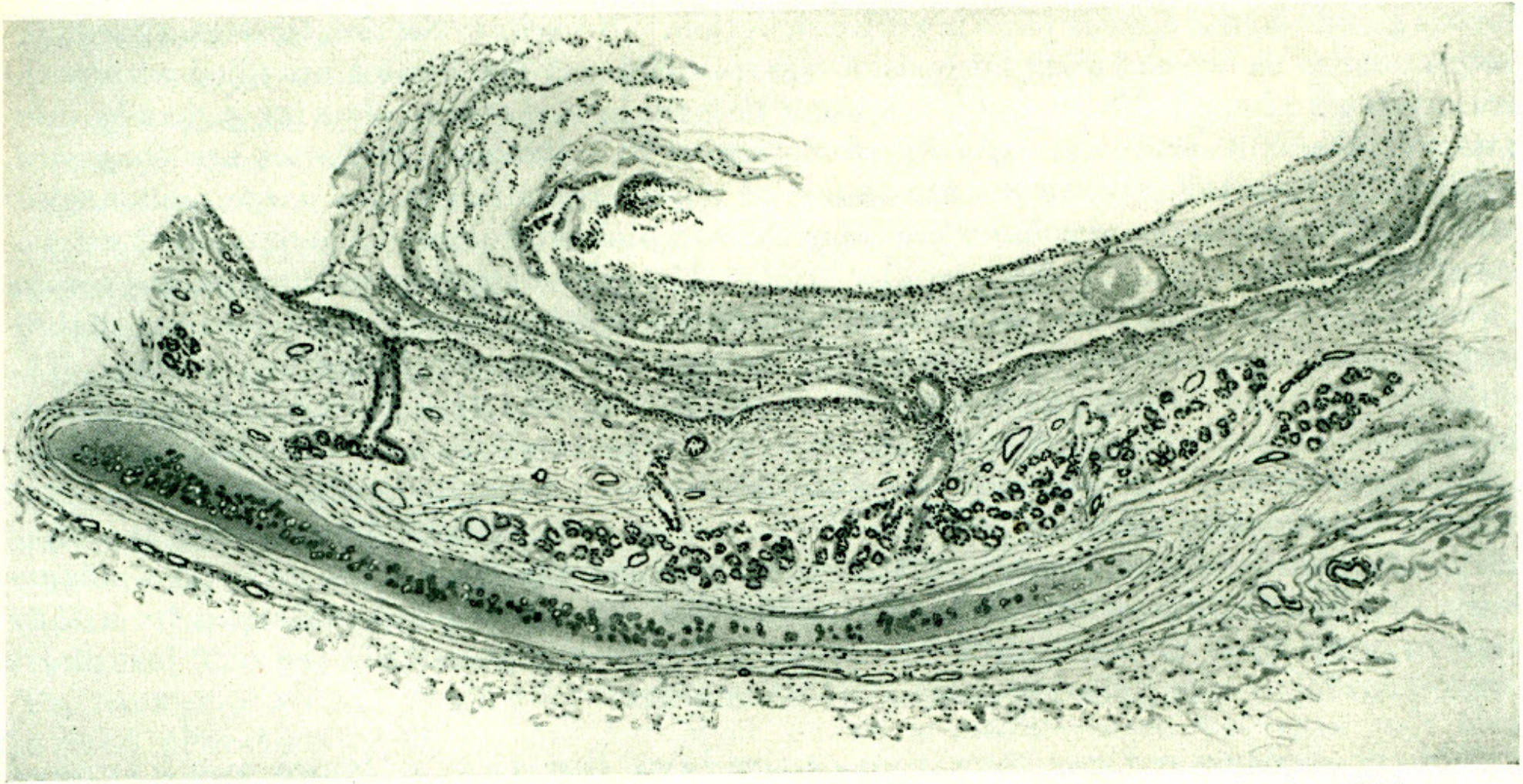

FIG. 28.—Case 16. Mustard-gas burn, 4 days' duration. Trachea. Low-power view, showing laminated false membrane attached to openings to mucous ducts