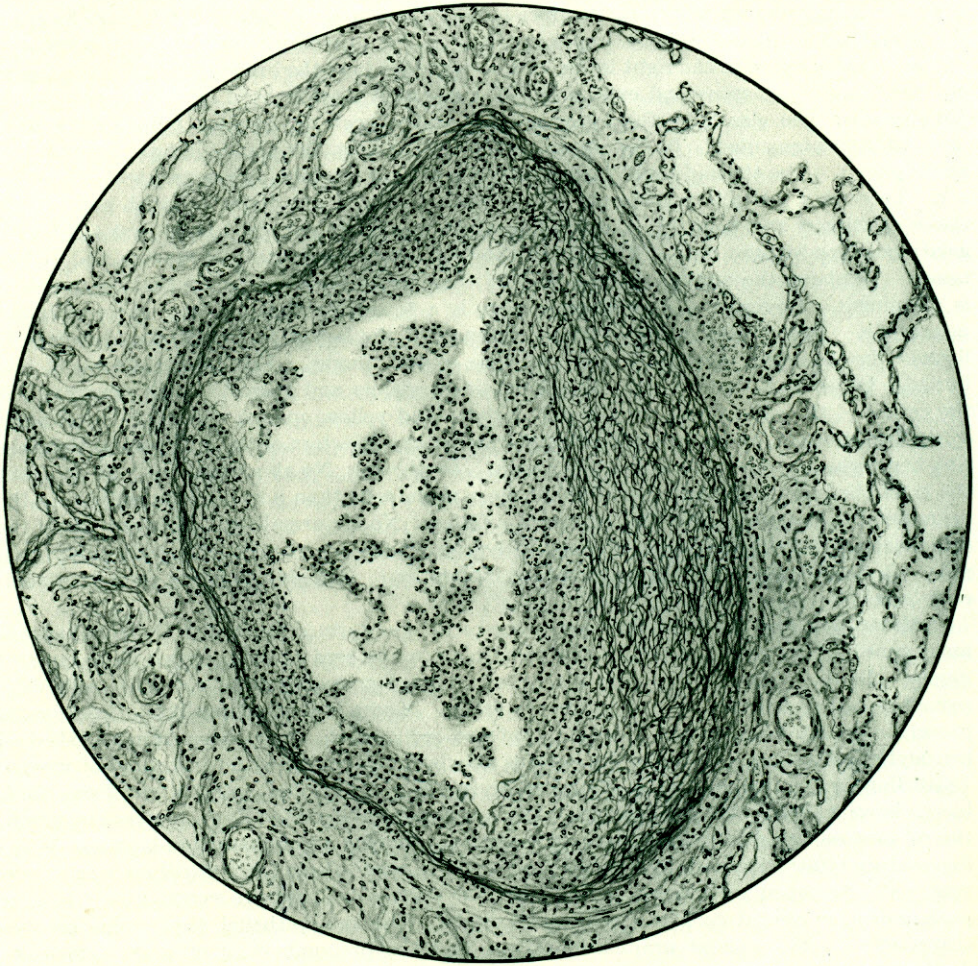

FIG. 29.—Case 25. Yellow, blue, and green cross shell, exposure 5 or 6 days before death. Dilated bronchiole lined with laminated fibrinopurulent membrane. Complete loss of epithelium