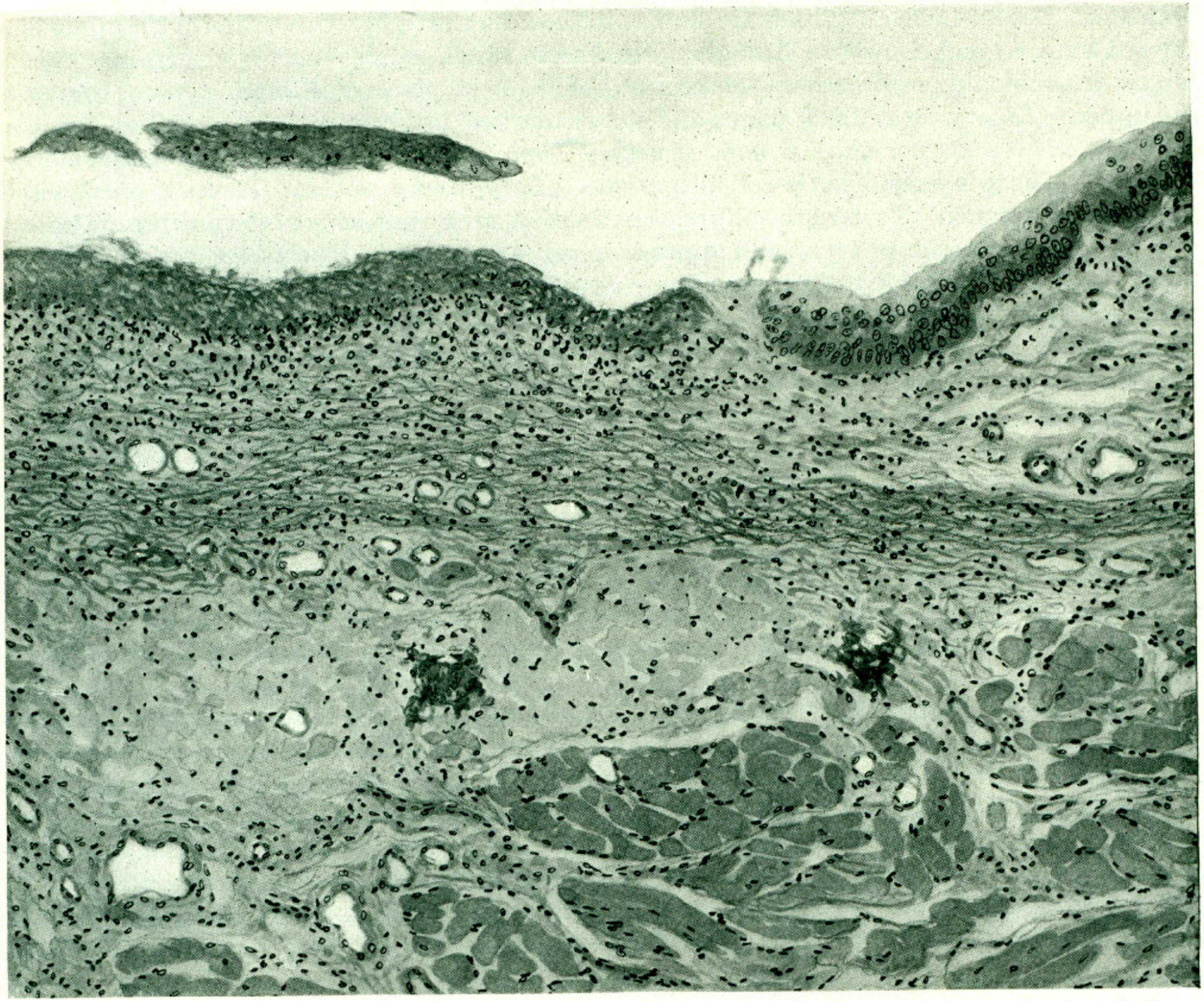

FIG. 31.—Case 61. Mustard-gas burn, 9 days' duration. Pharynx. Localized superficial necrosis of epithelium with inflammatory reaction