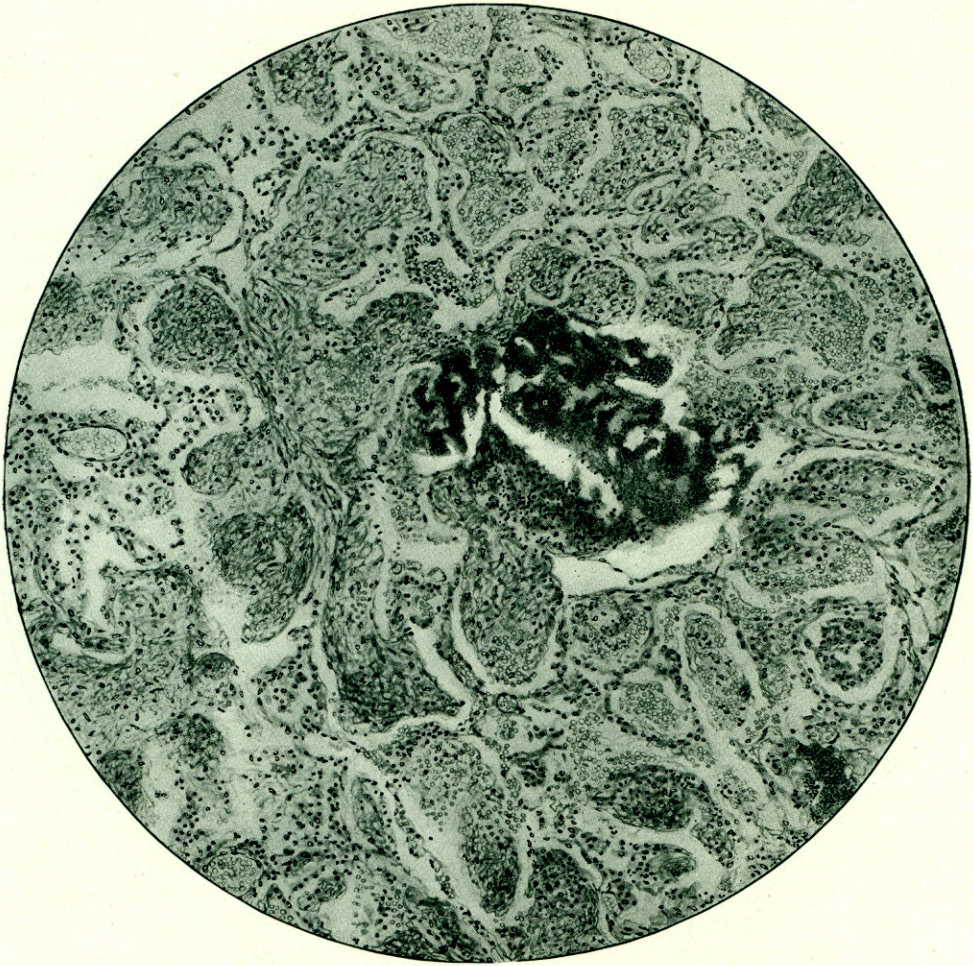

FIG. 35.—Case 89. Mustard-gas burn, 20 days' duration. Lung. Area of bacterial necrosis with fibrinopurulent material in the adjacent alveoli