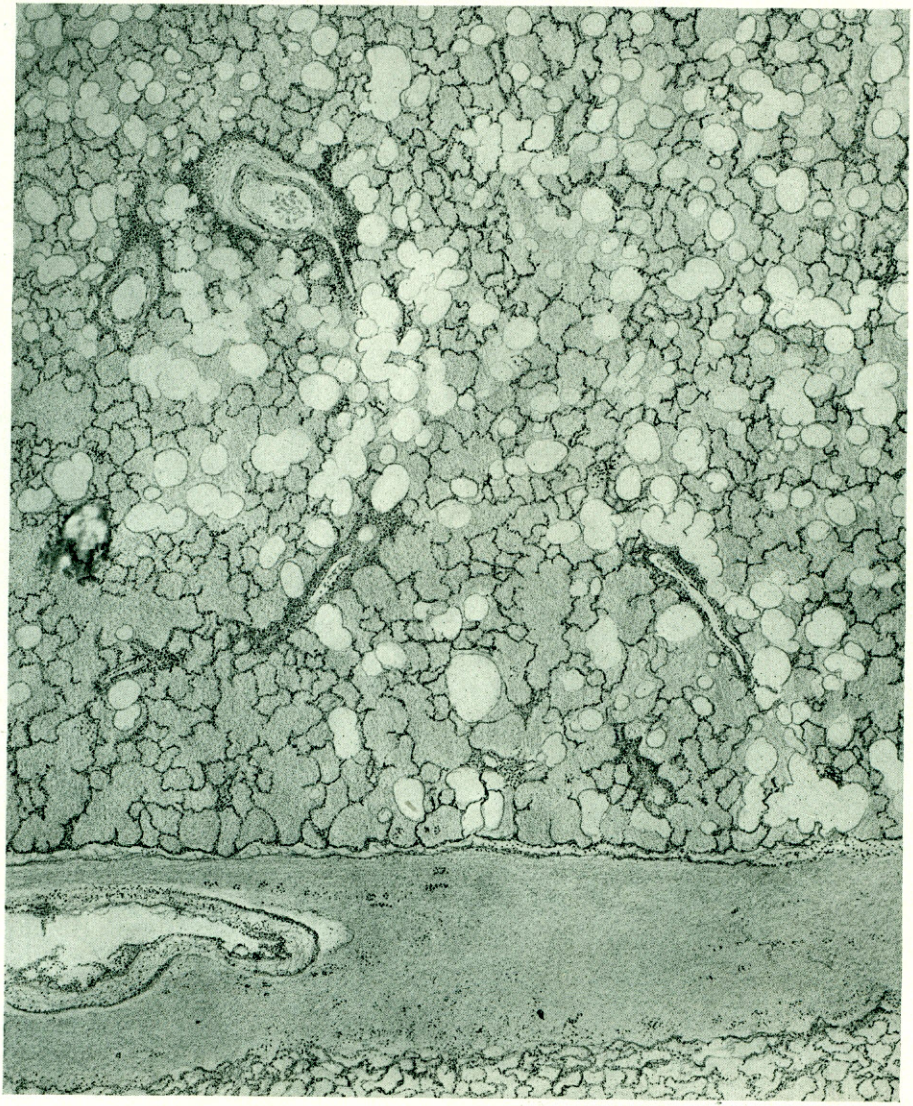

FIG. 40.—Case 106. Lung. Section (a) Edema of alveoli and interlobular septum