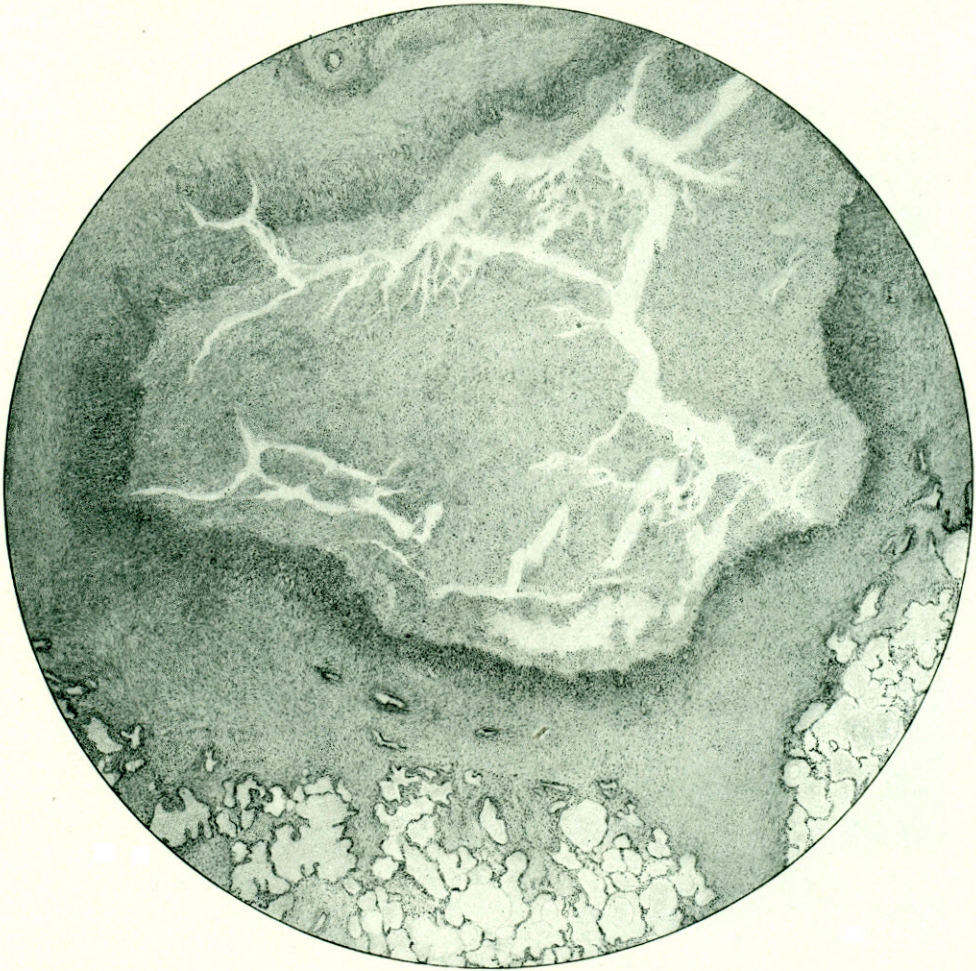

FIG. 41.—Case 106. Lung. Section (b) through cavity in the upper lobe