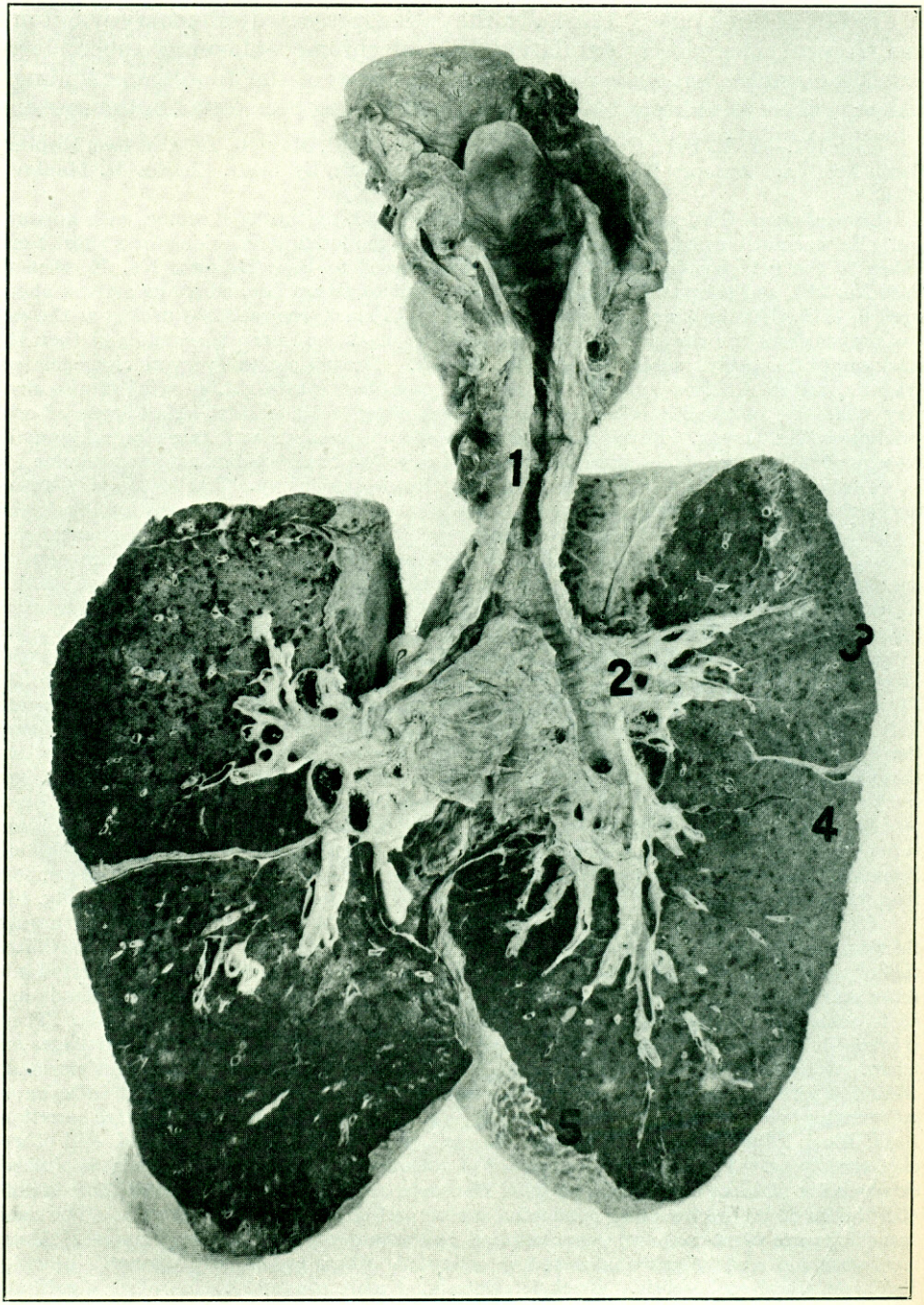

FIGURE 44.—Case 107. Late stricture of trachea showing mustard-gas inhalation