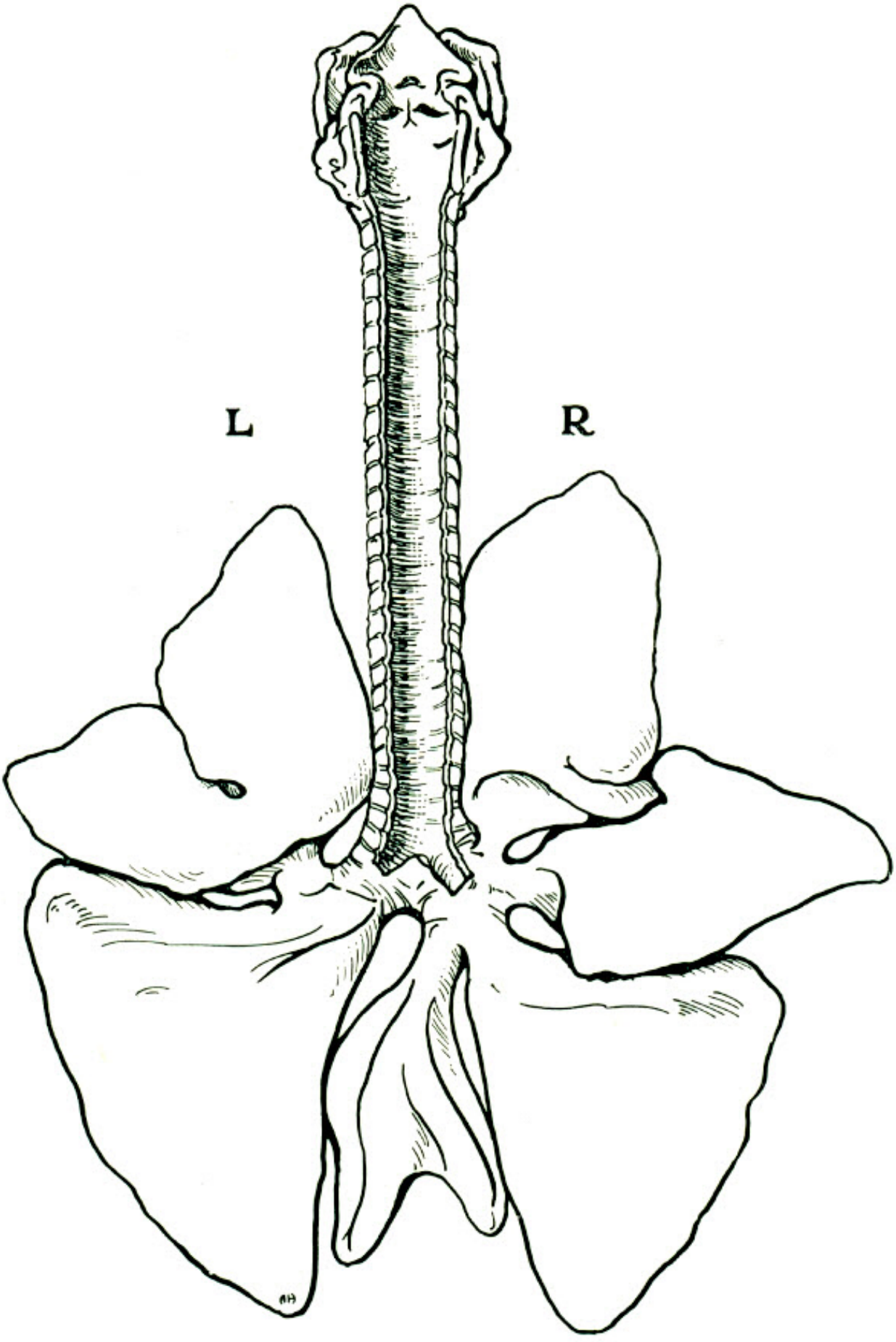


FIG. 46.—Diagram of dog's respiratory tract viewed from behind. The interlobular fissures and the accessory caudate lobe are well shown