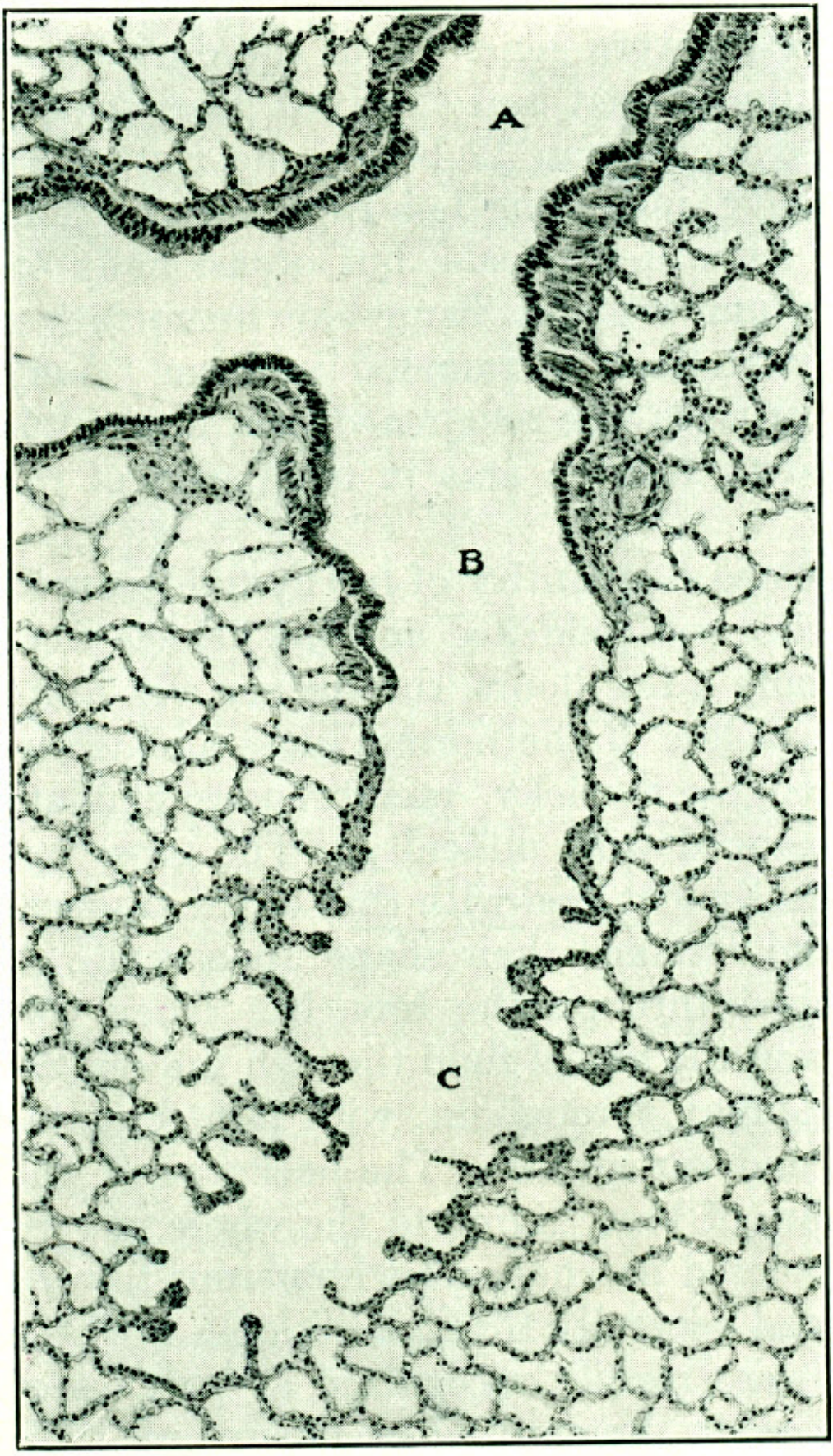

FIG. 48.—Normal bronchus. Bronchiolar termination in a dog's lung, showing transition from high ciliated epithelium of bronchi to the flattened epithelium of the infundibula