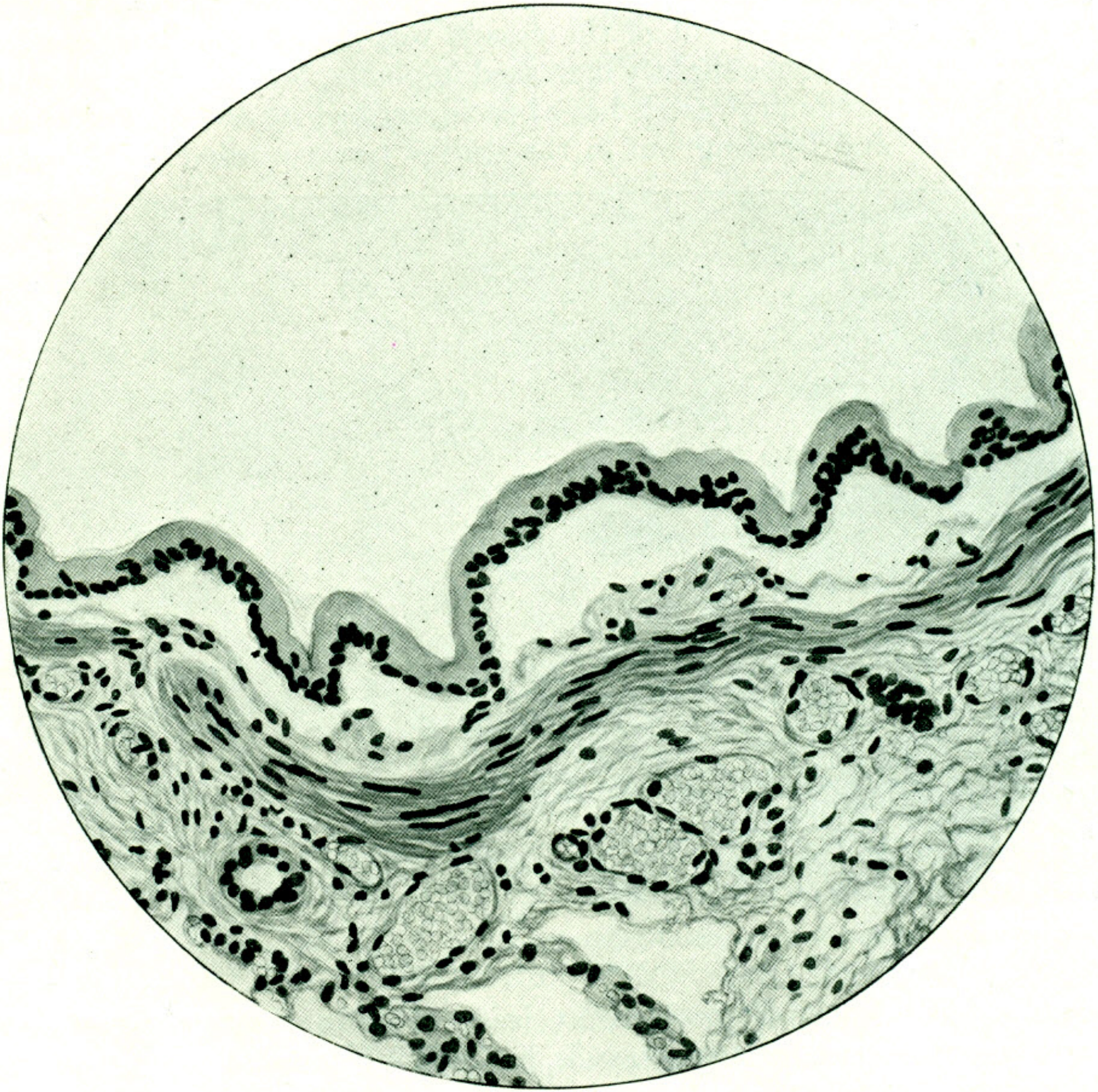

FIG. 50.—Higher magnification of necrotic lining shown in Figure 49