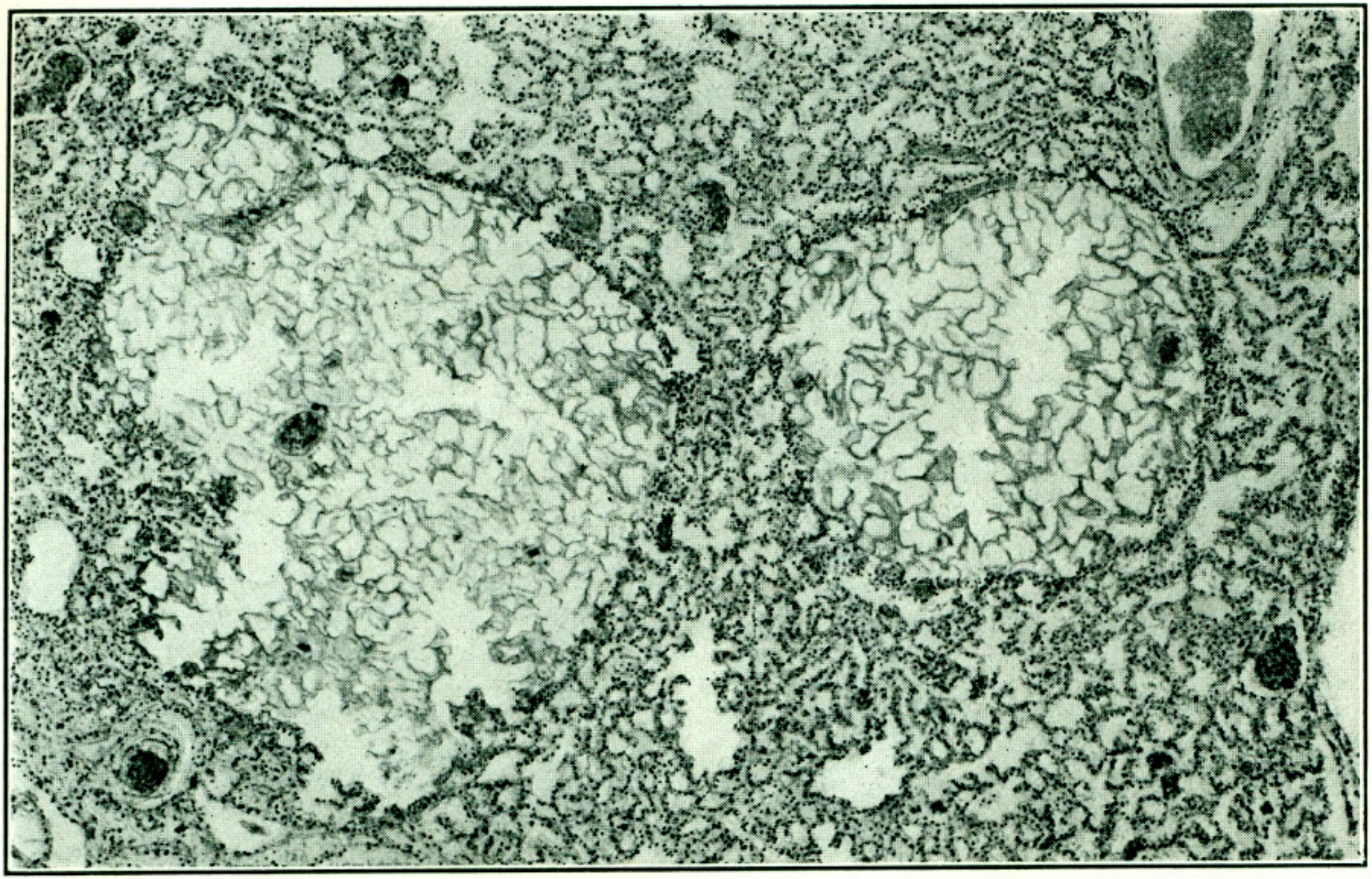

FIG. 51.—Multiple areas of focal necrosis in lung of dog dying 20 hours after chlorine gassing