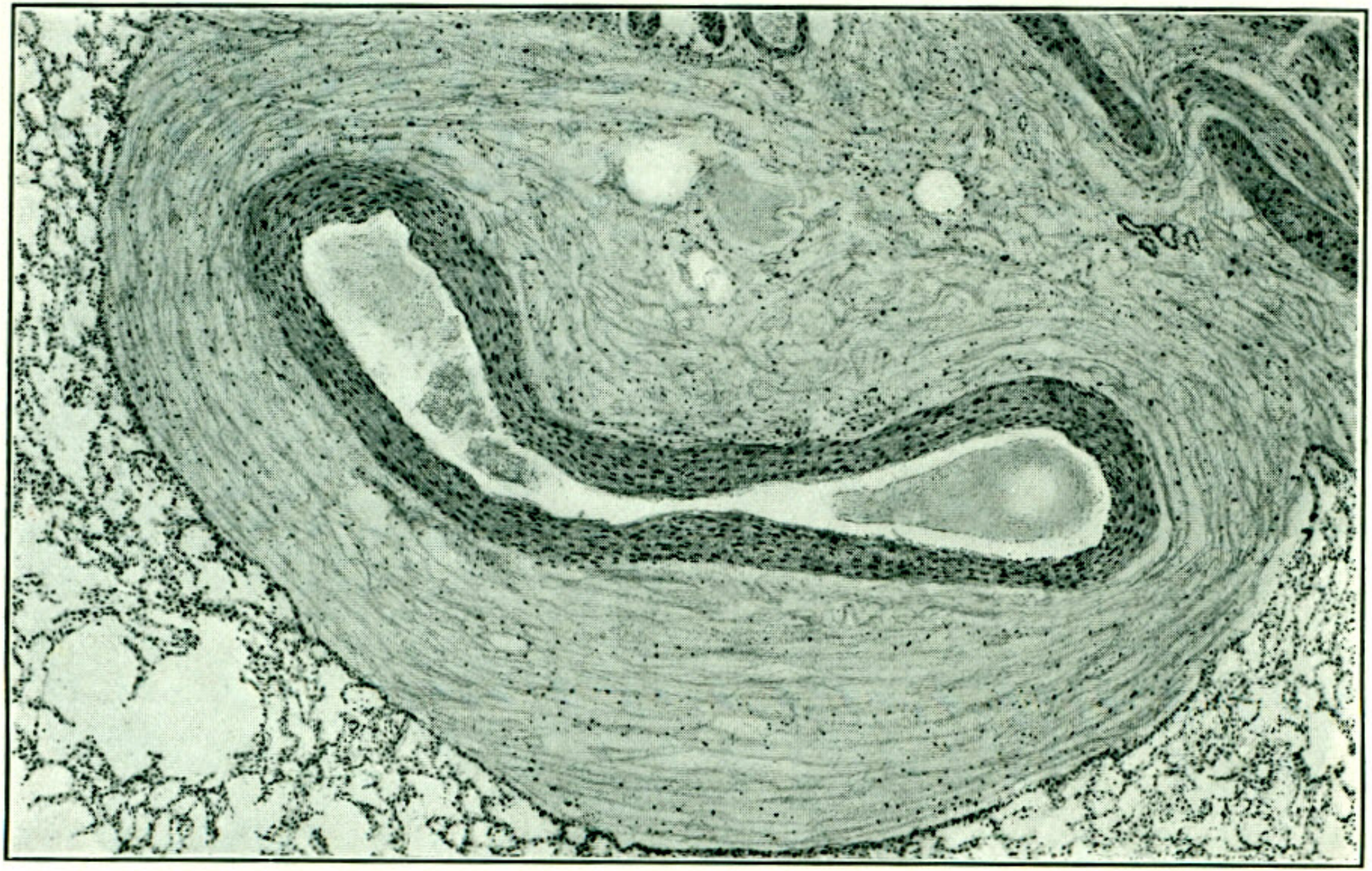

FIG. 53.—Marked perivascular edema in acute death from chlorine. The lymphatic channels of the adventitia are widely distended with fluid