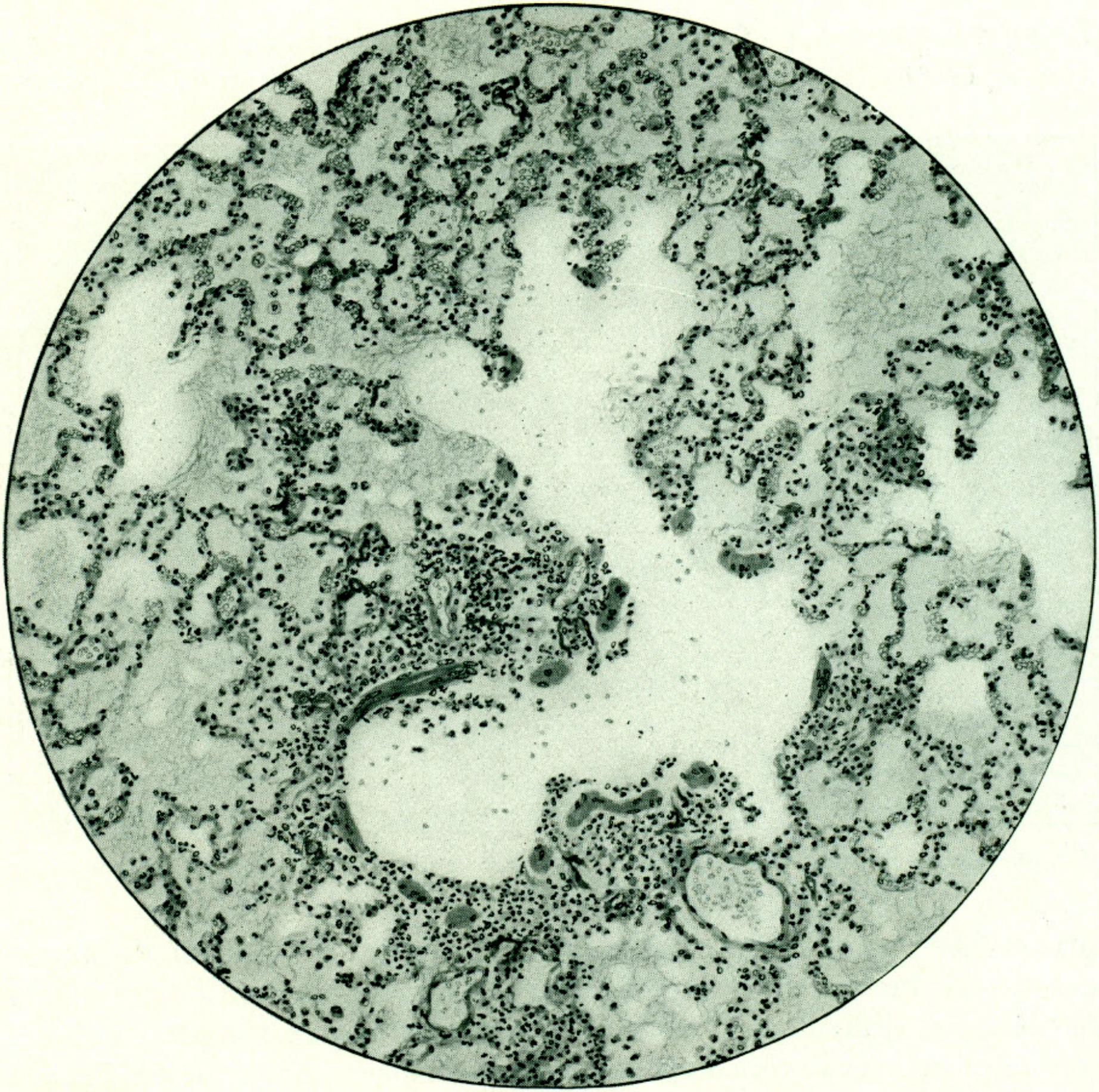

FIG. 54.—Early inflammatory reaction in the lungs found six hours after exposure to chlorine. The cells of the exudate are chiefly polynuclears which accumulated in and about an atrium