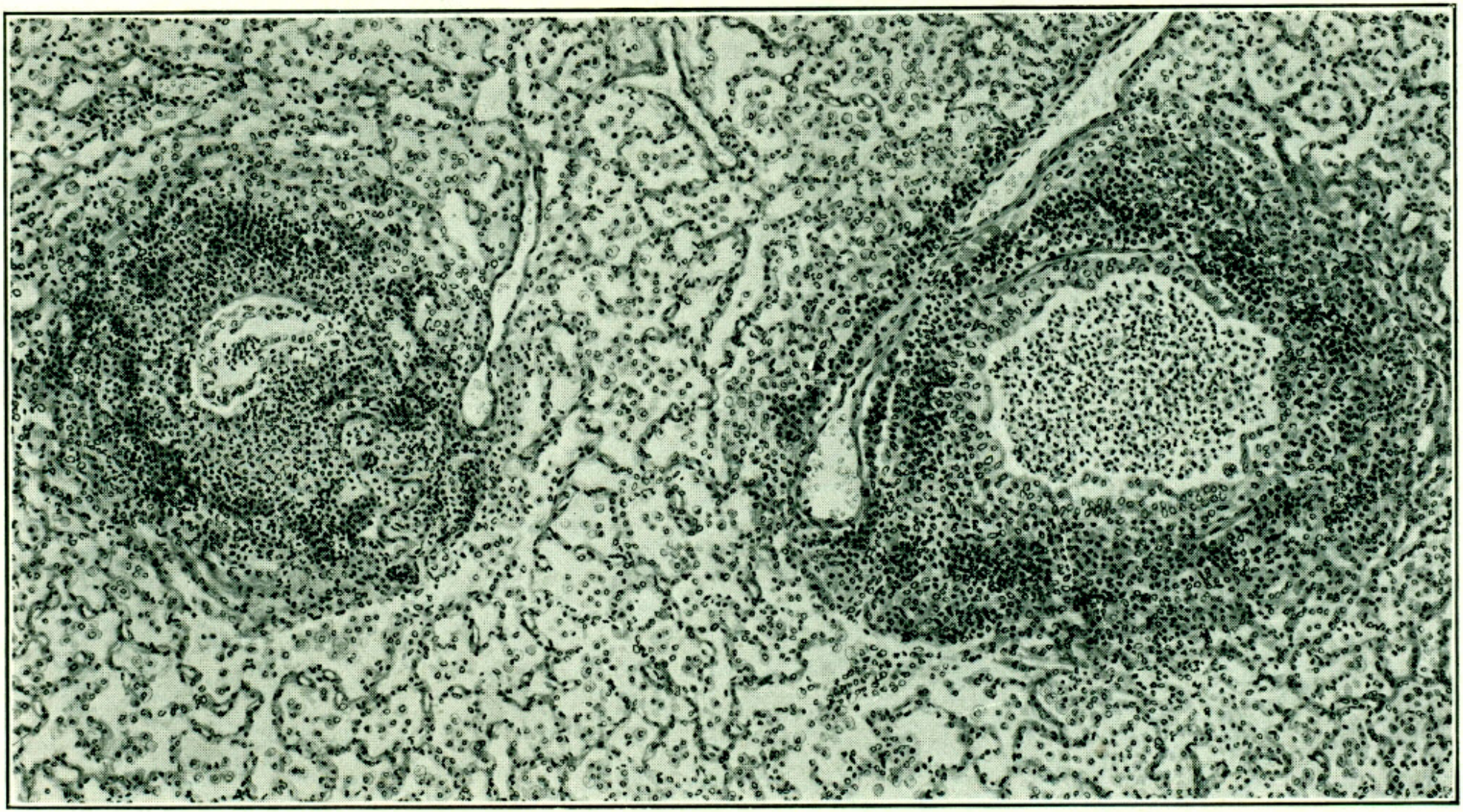

FIG. 56.—Purulent bronchitis in a dog dying 23 days after exposure to chlorine. The cells in the bronchi are chiefly polynuclears, but in the adjacent alveoli are many large mononuclear cells