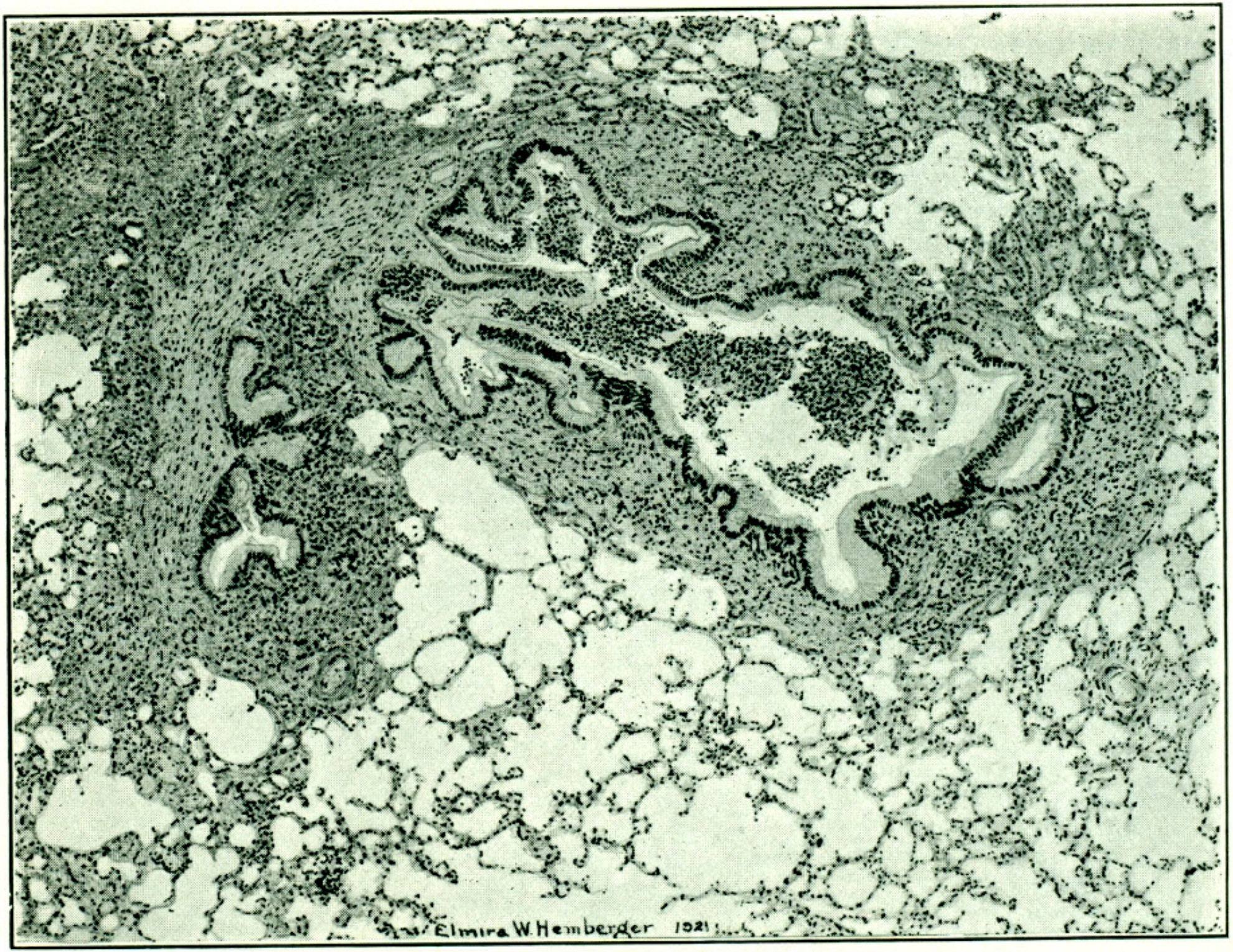

FIG. 58.—Chronic bronchitis and patchy emphysema in a dog dying 58 days after chlorine gassing