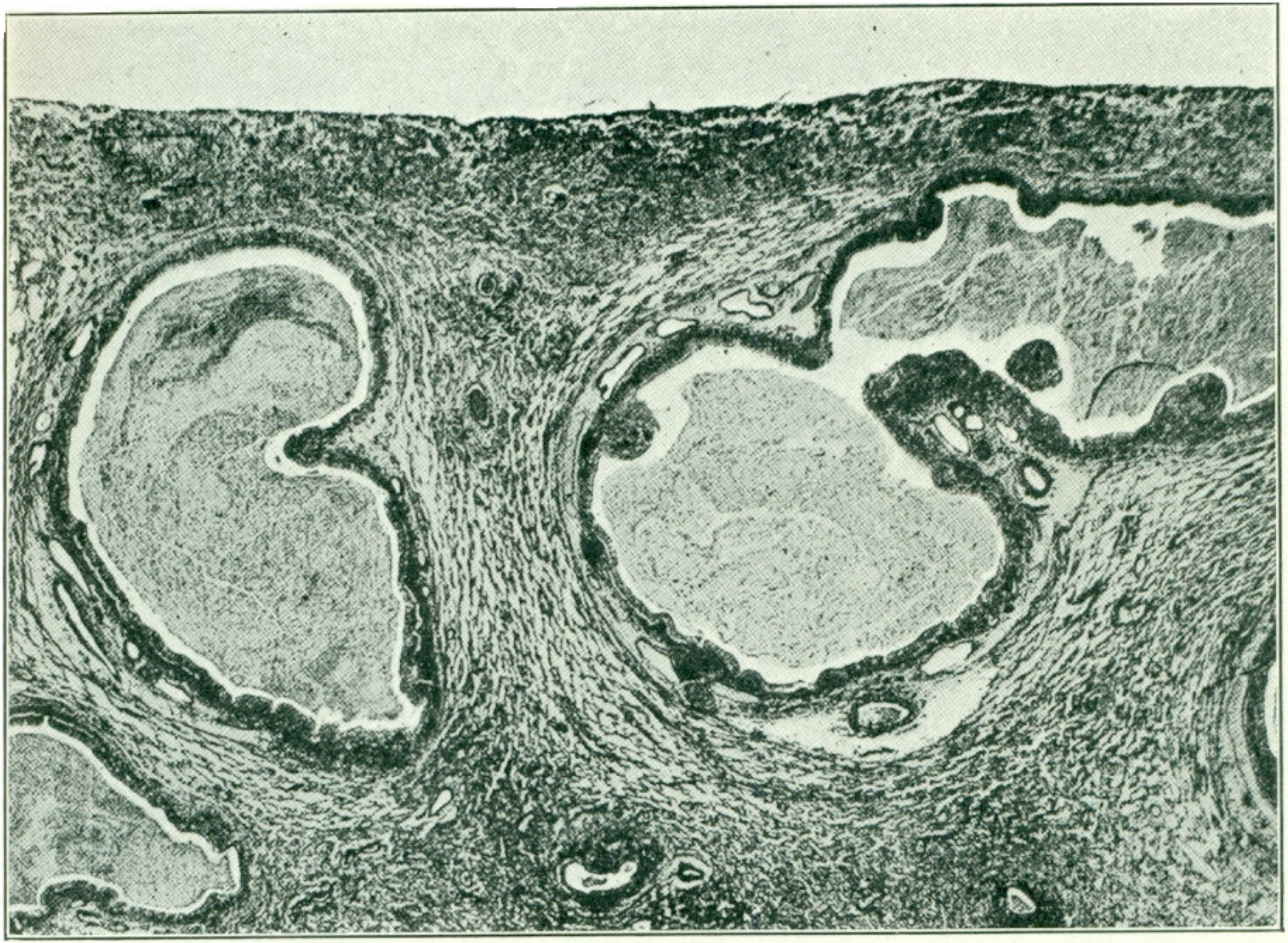

FIG. 59.—Bronchiectatic cavities in lungs of dog dying 39 days after chlorine gassing. The lung tissue supplied by these bronchi is completely atelectatic