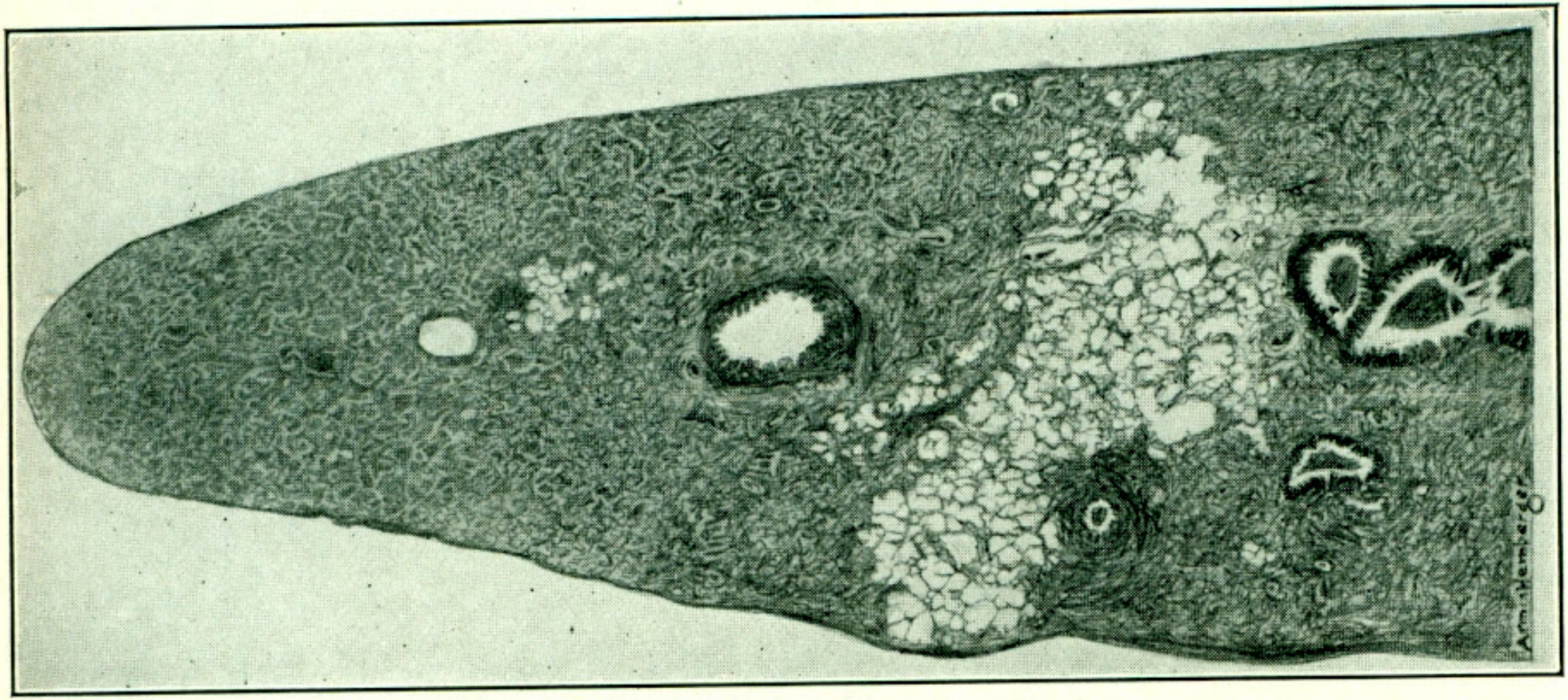

FIG. 63.—Low magnification of lung of dog dying two months after exposure to chlorine. Chronic bronchitis and bronchiectasis with atelectasis and occasional patches of emphysema