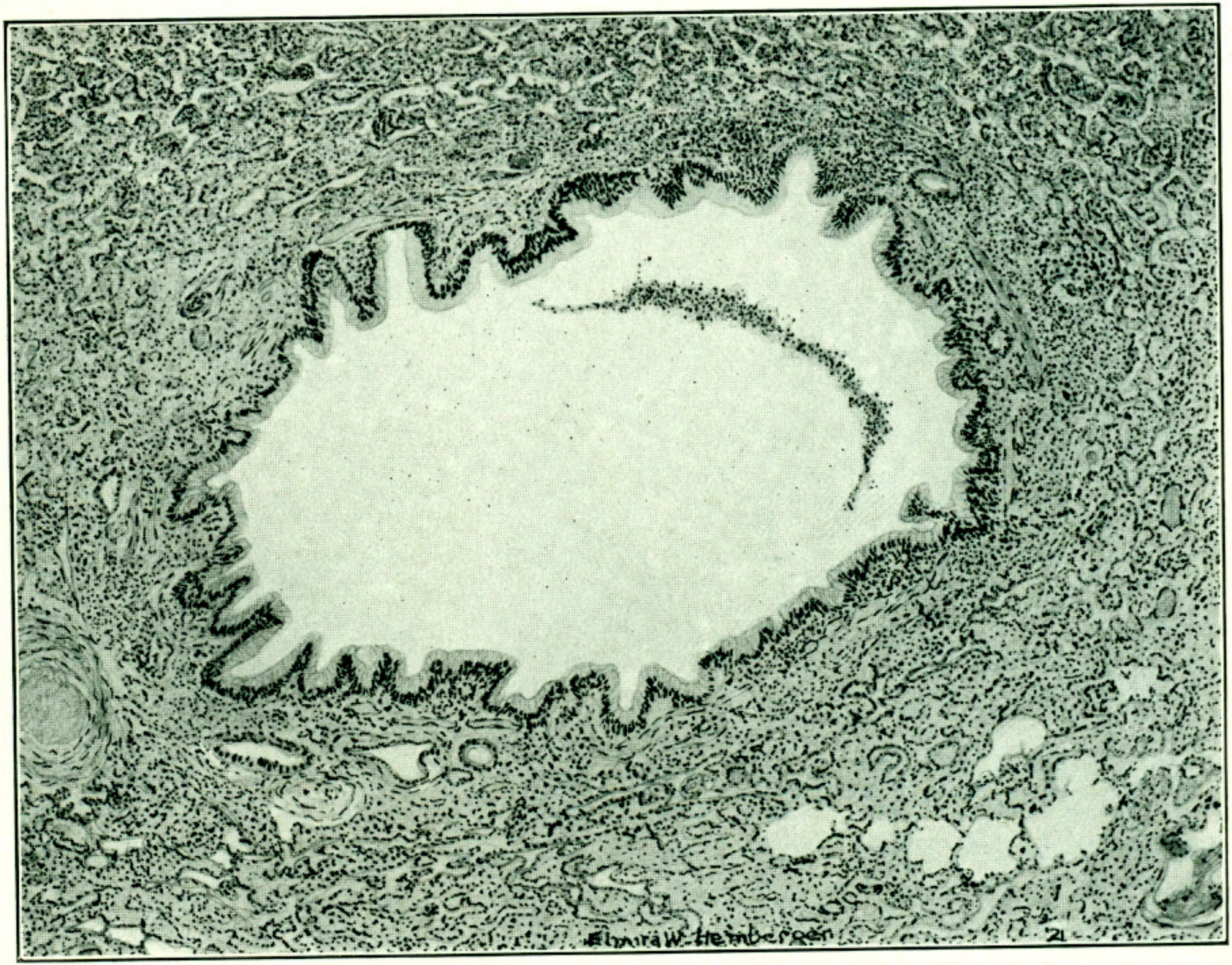

FIG. 64.—Higher magnification of the bronchi shown in Figure 63. Bronchus is moderately dilated. Adjacent lung tissue is atelectatic