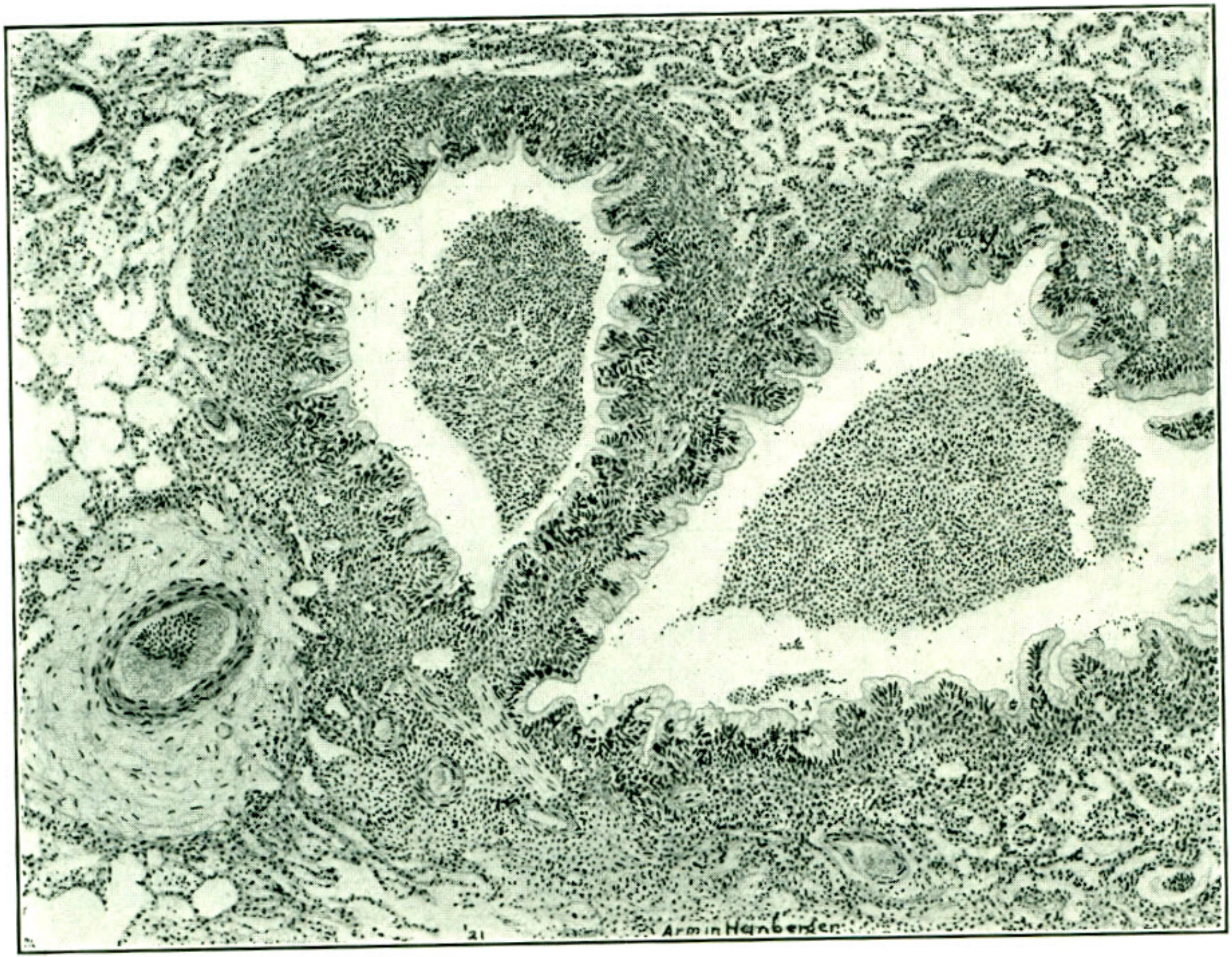

FIG. 65.—Higher magnification of two bronchi shown in Figure 63. Lumina are filled with a cellular inflammatory exudate. There is also a chronic peribronchial reaction