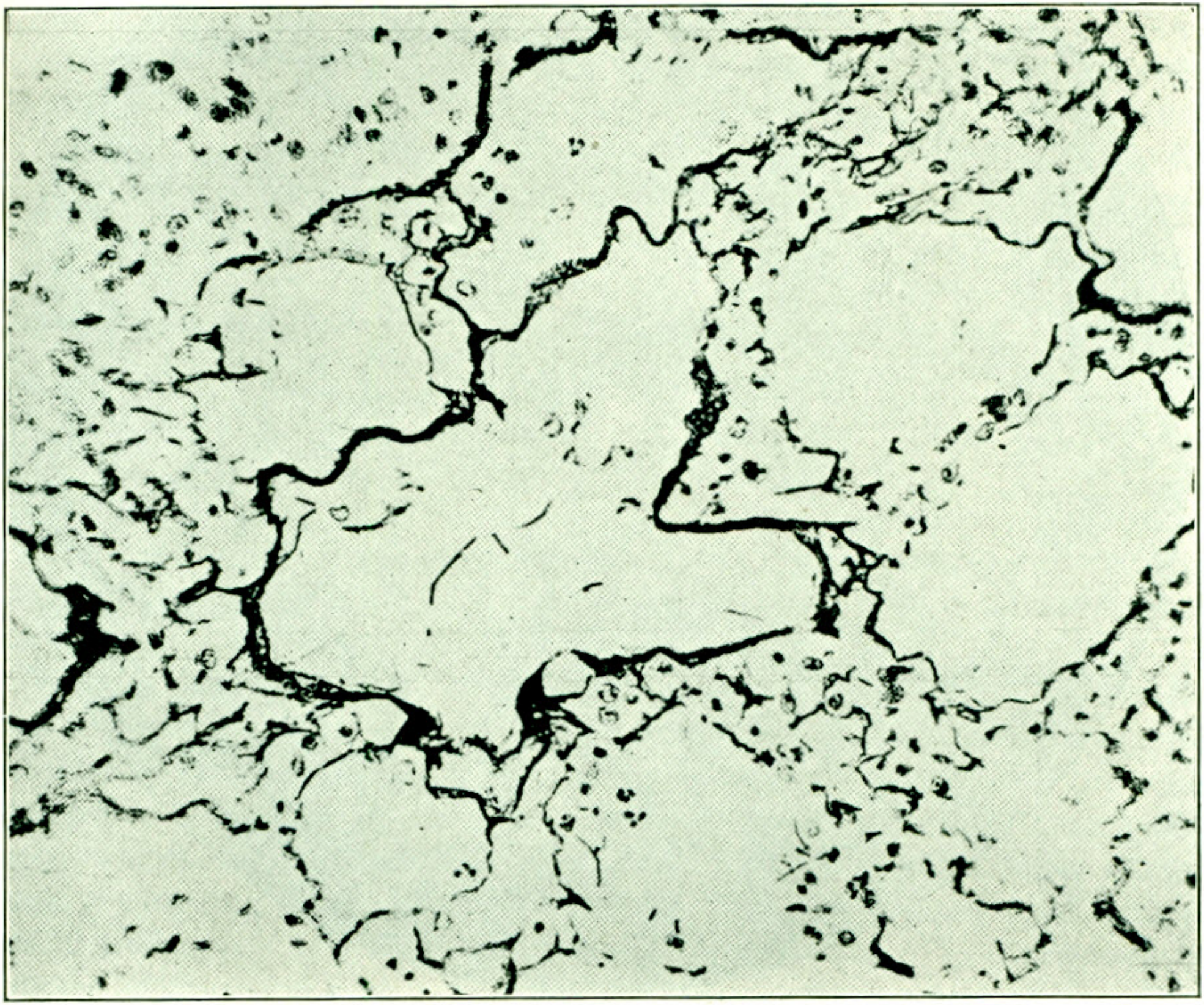

FIG. 67.—Higher magnification of an area shown in Figure 66. In places the fibrin stain extends across the septa