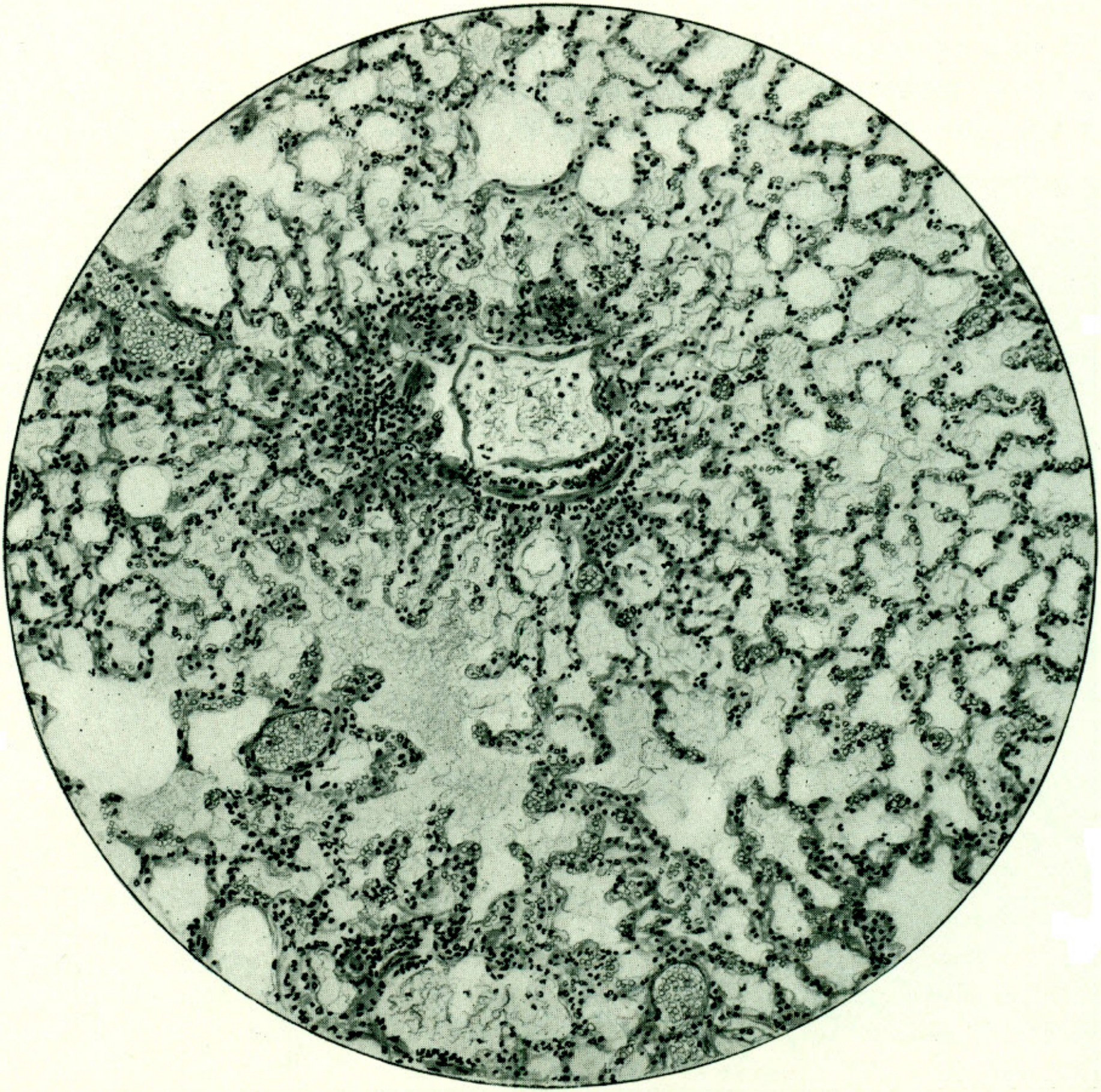

FIG. 68.—Early inflammatory reaction about bronchiole 18 hours after gassing. Cells are chiefly polynuclears. There is a generalized edema of the lung tissue