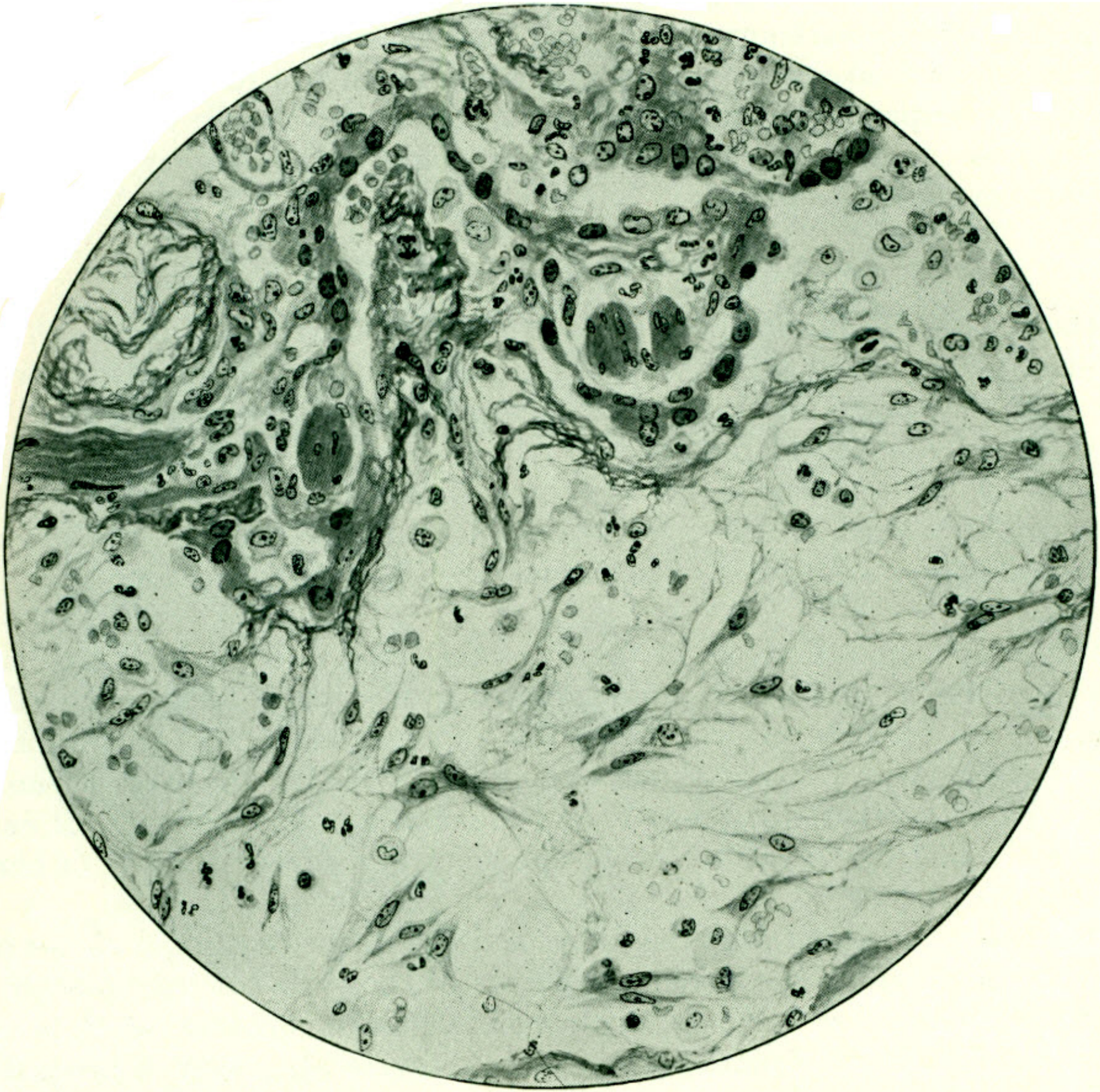

FIG. 71.—Higher magnification of bronchial wall shown in Figure 70. Fibroblasts are seen extending in a loose growth from the submucosa. One mitotic figure is present