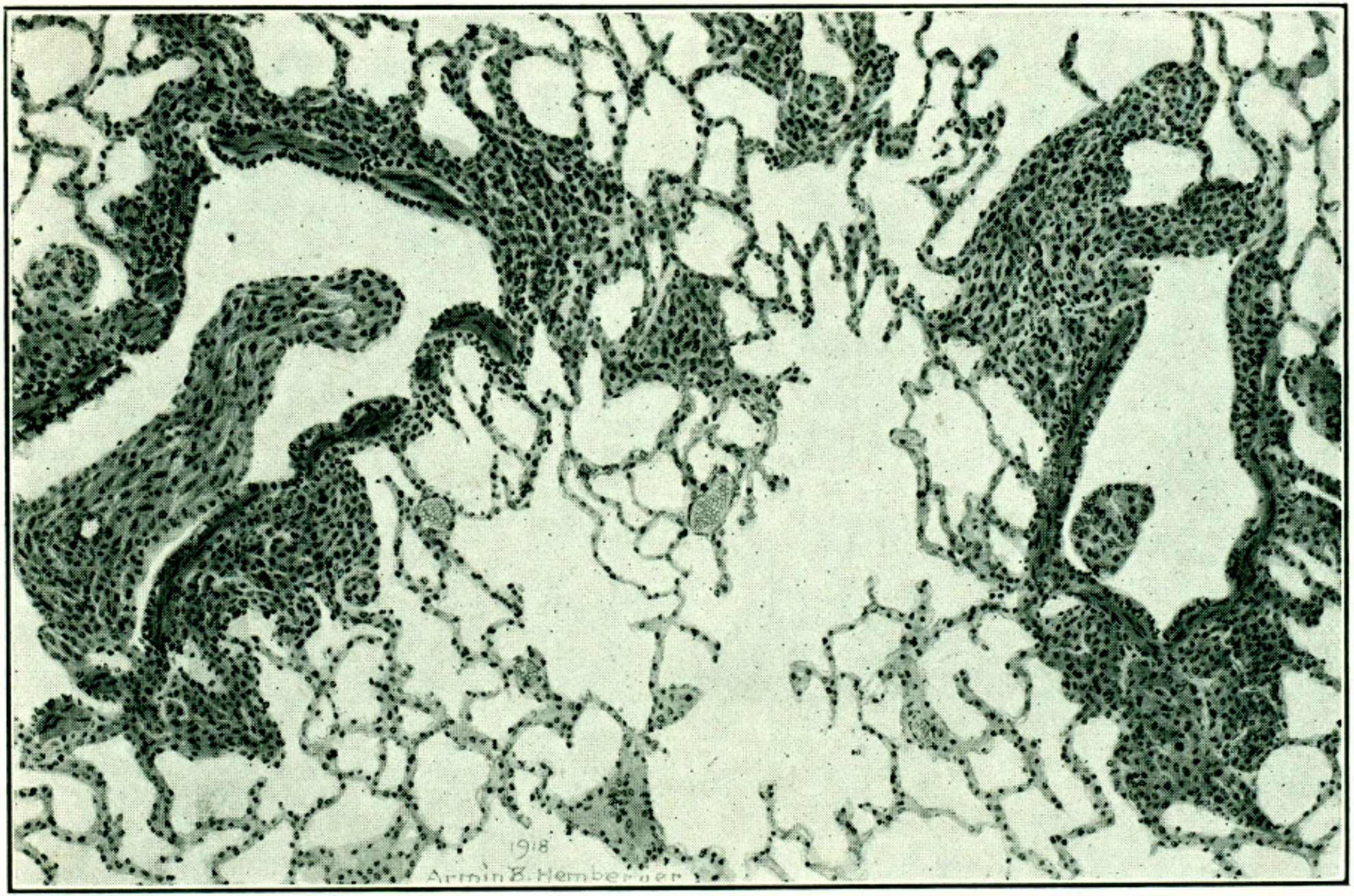

FIG. 73.—Higher magnification of two bronchi shown in Figure 72. The peribronchial thickening and the polypoid growths in the lumina are well shown