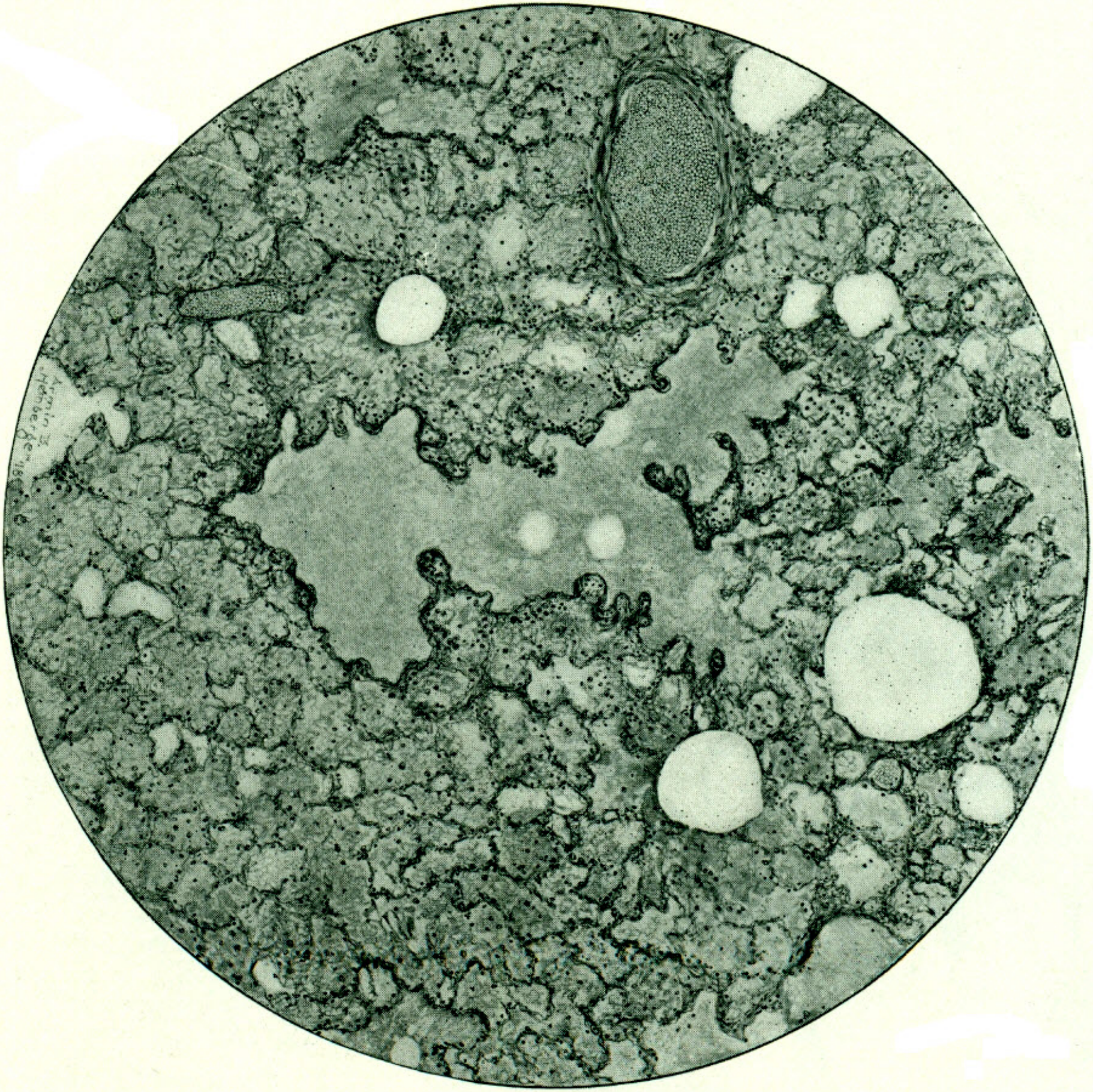

FIG. 75.—Widespread edema of lung associated with acute death from chloropicrin. Note occasional clear spaces (air bubbles) in some of the alveoli