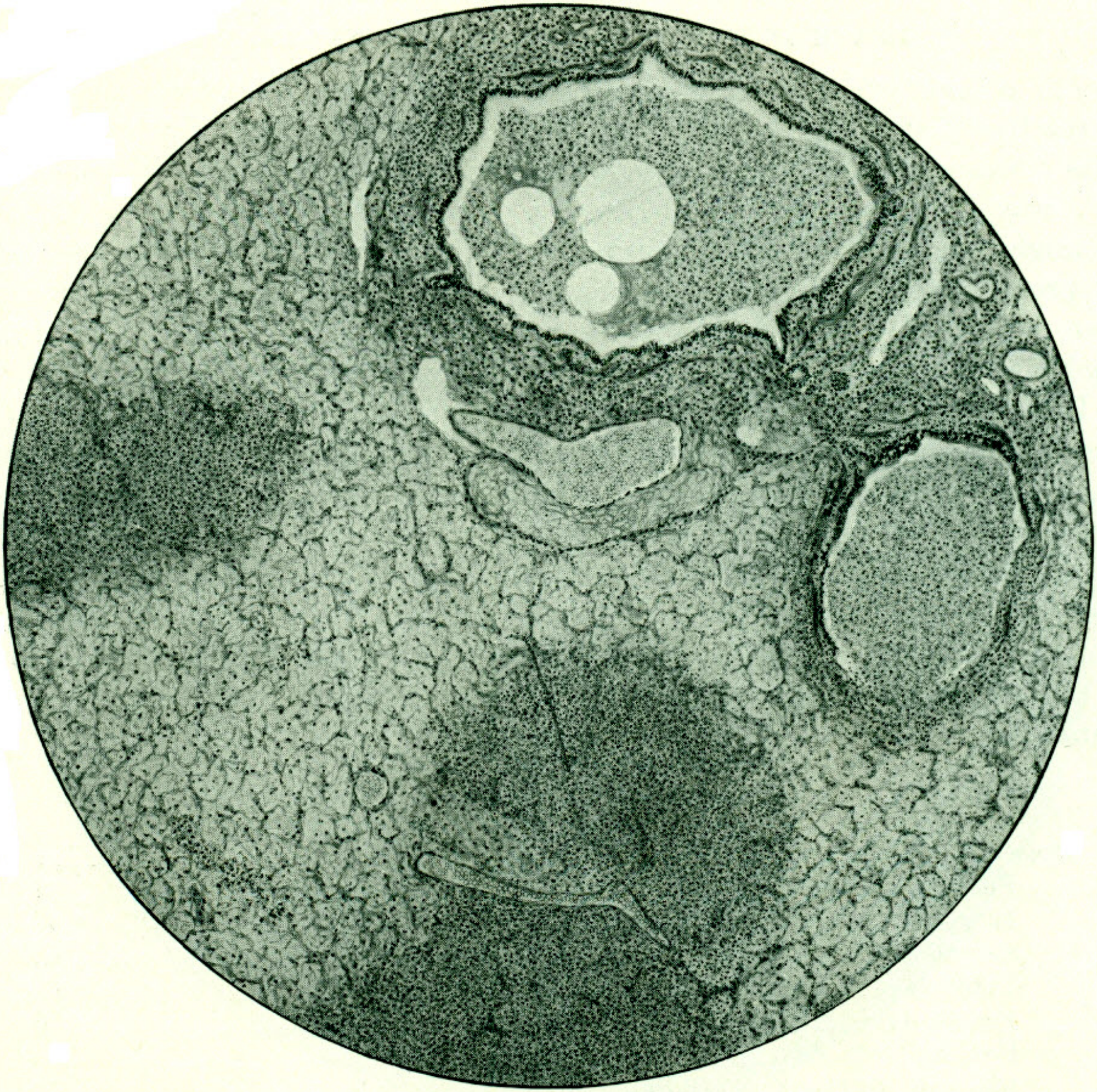

FIG. 76.—Acute bronchitis and bronchopneumonia causing death three days after exposure to chloropicrin. The lung tissue separating the pneumonic patches is markedly edematous