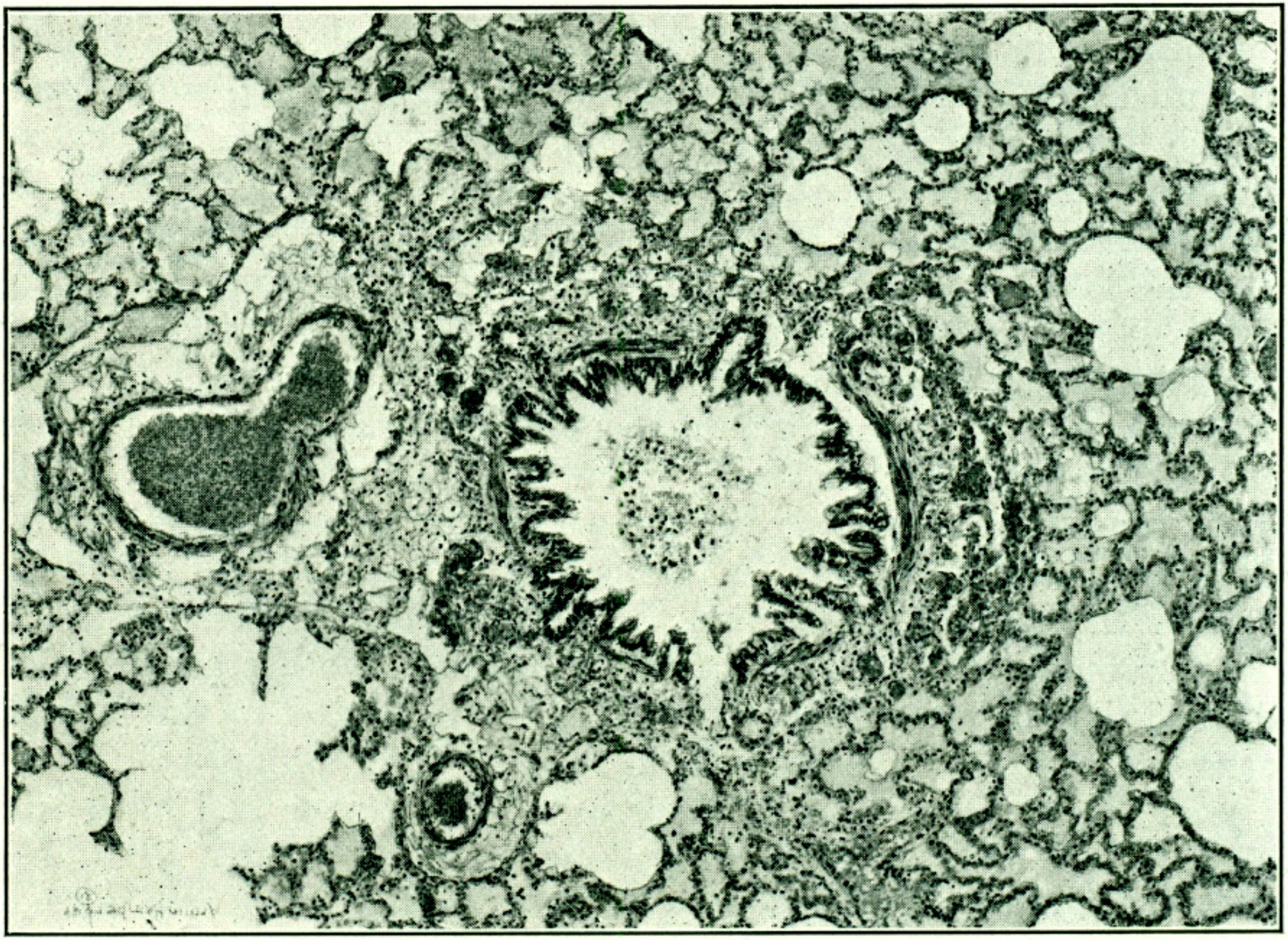

FIG. 80.—Widespread edema of lung in acute death from dichlorethylarsine. The clear round spaces indicate the presence of air bubbles