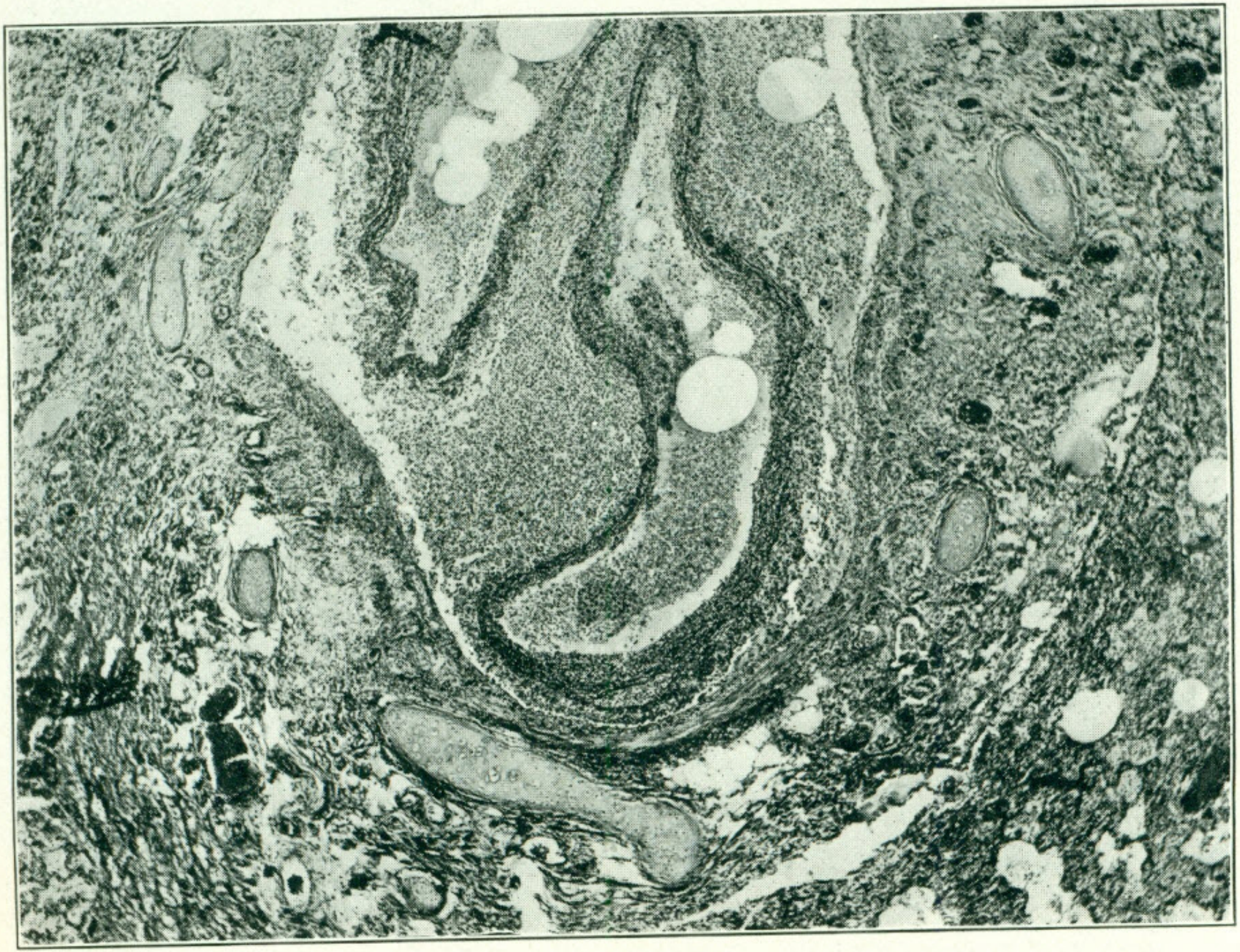

FIG. 81.—Necrotization of the bronchial lining associated with acute death from dichlorethylarsine. A few air bubbles are seen in the exudate filling the lumen