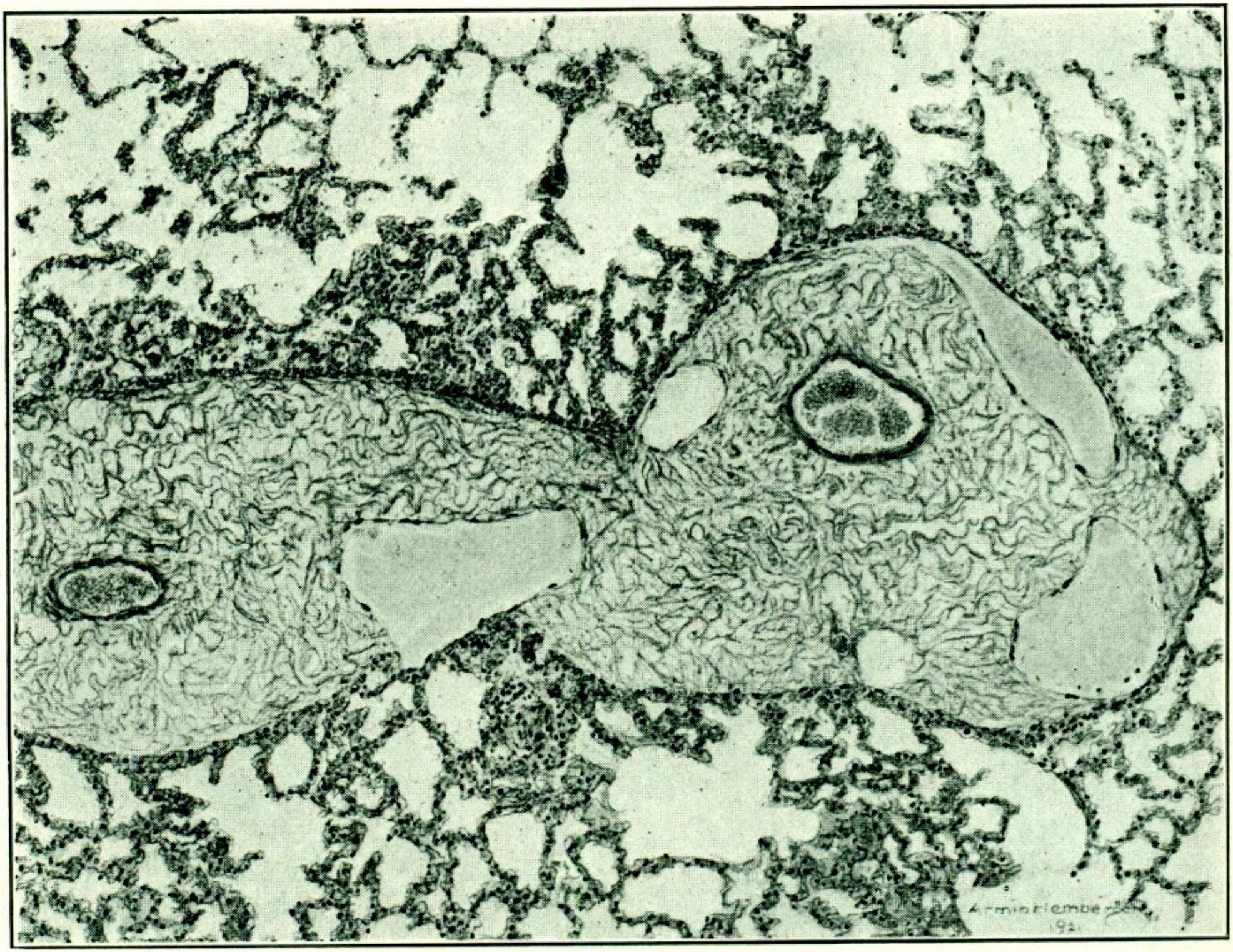

FIG. 82.—Marked perivascular edema and dilatation of lymphatics in acute dichlorethylarsine gassing