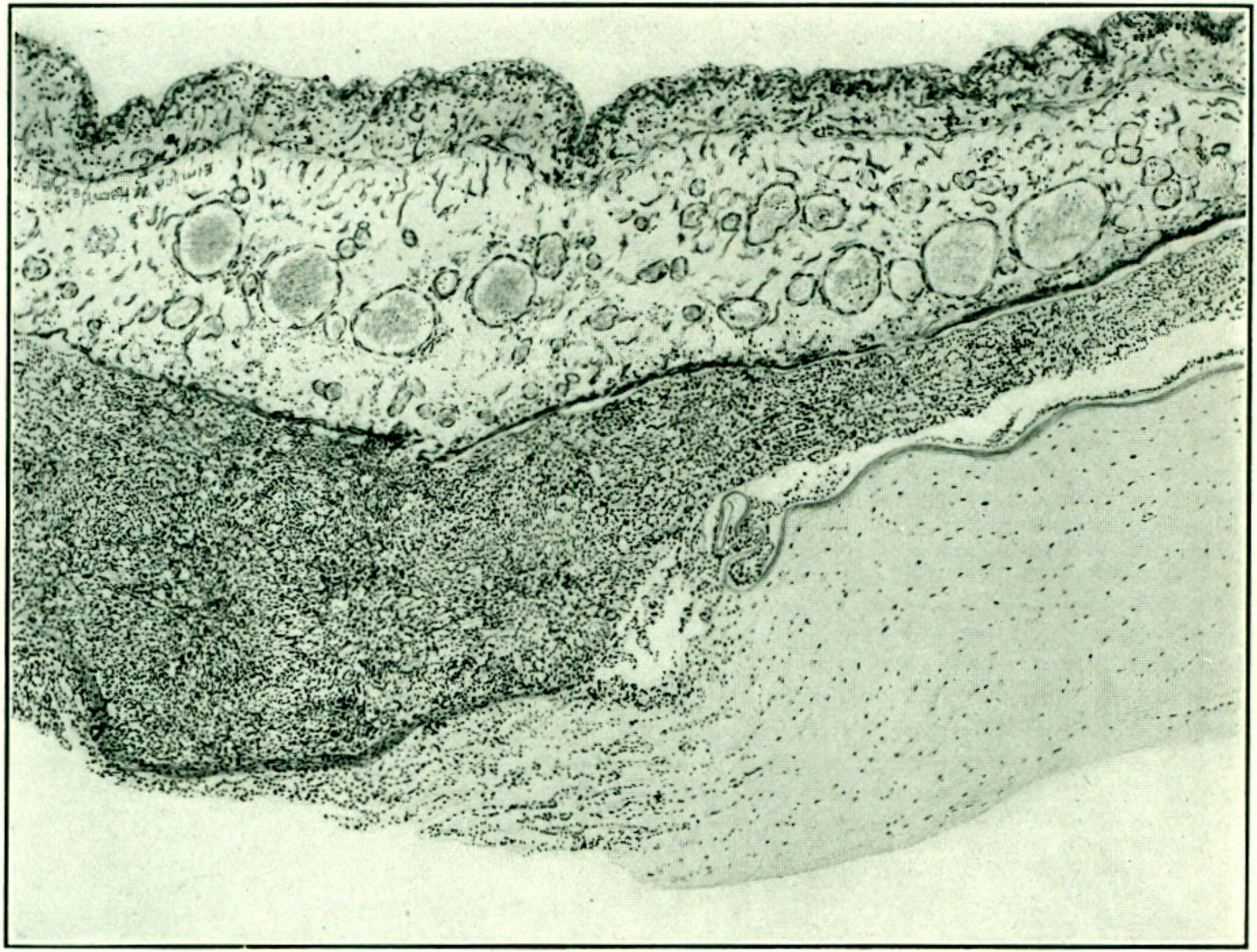

FIG. 83.—Ulceration of cornea following exposure to dichlorethylarsine. Perforation of the cornea has taken place with infection of the anterior chamber