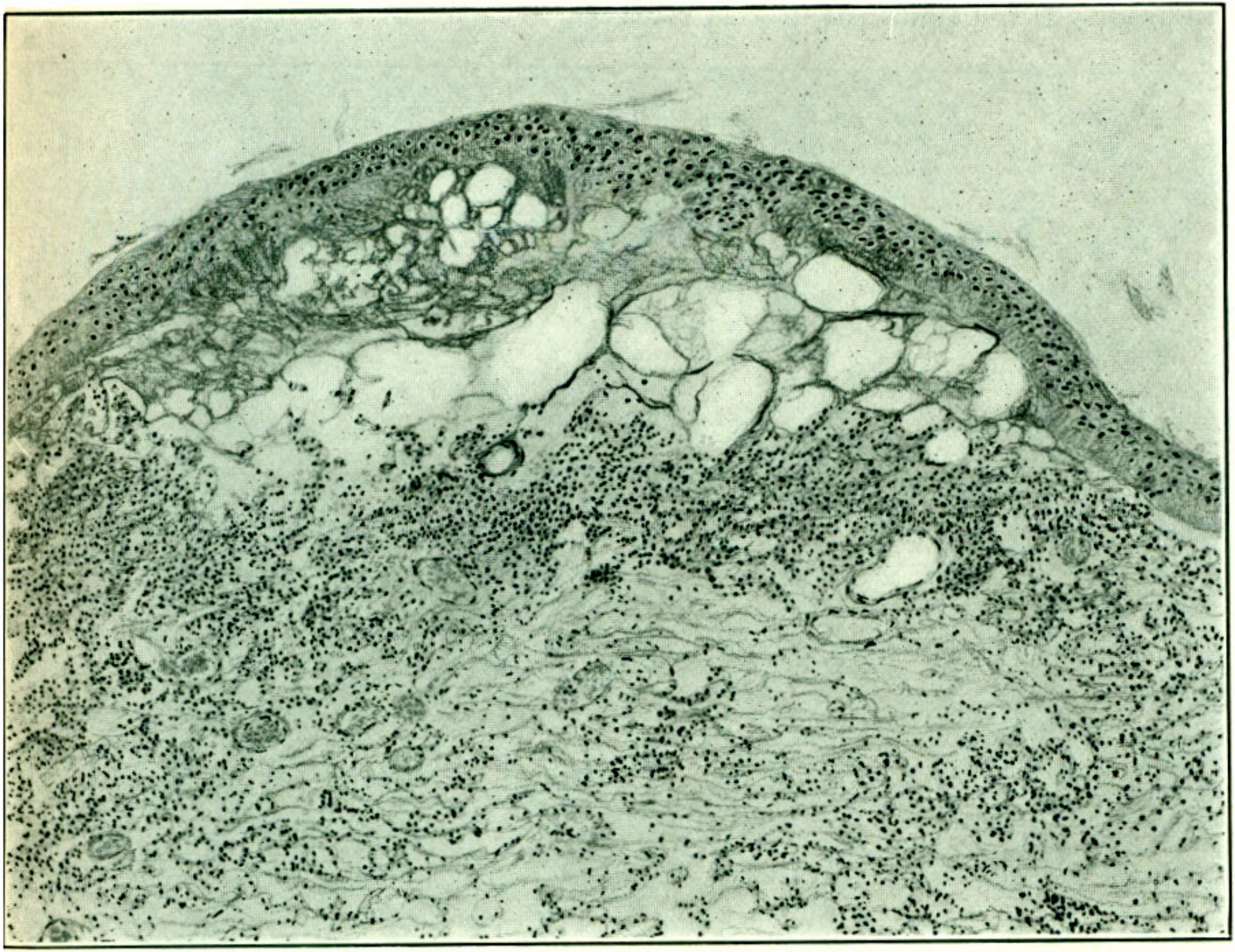

FIG. 85.—A higher magnification of one of the blisters shown in Figure 84. The fluid of the bleb is rich in fibrin which stains deeply