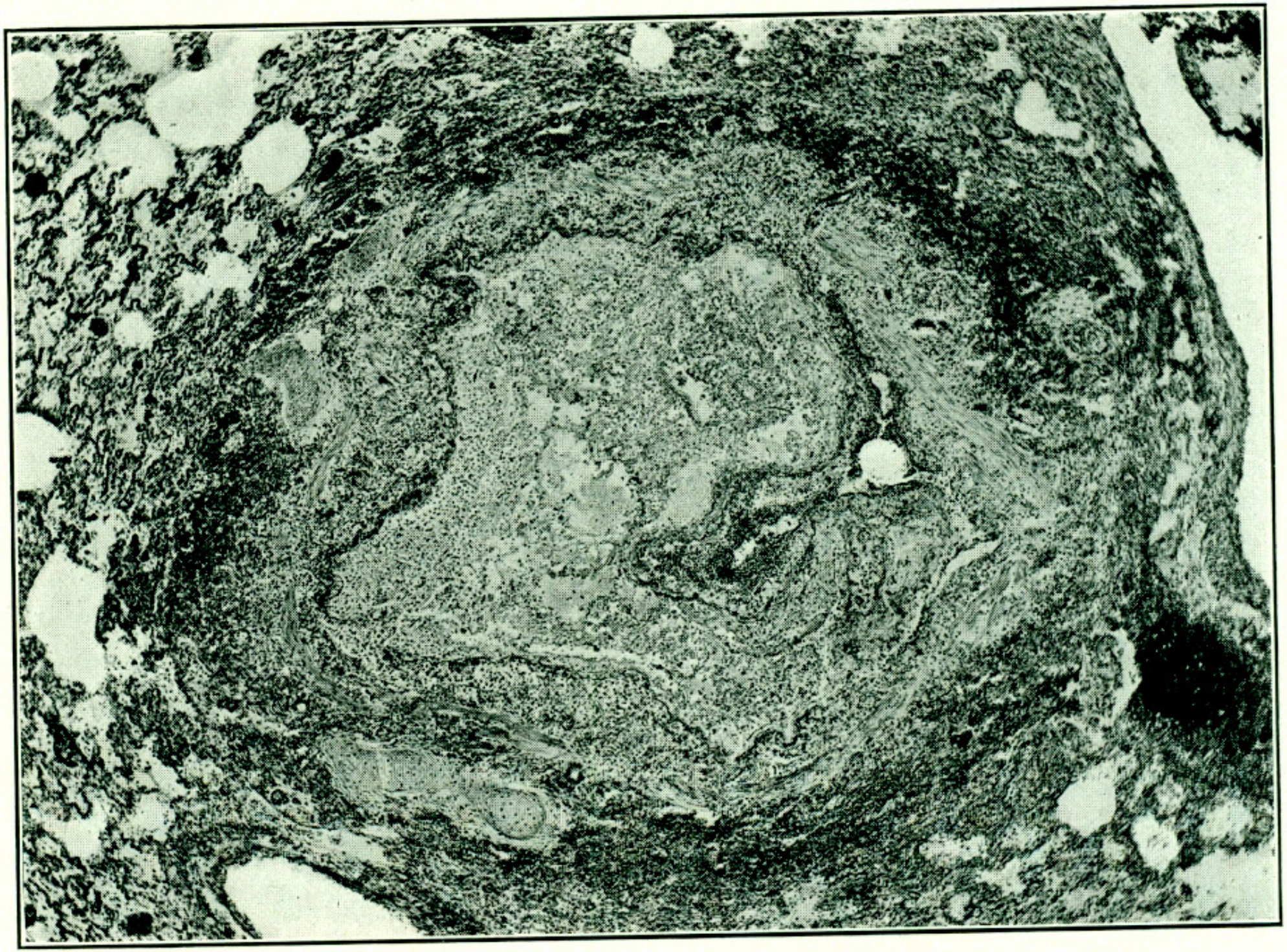

FIG. 86.—Complete necrosis of the mucosa of a large bronchus resulting from dichlorethylarsine gassing. There is a marked inflammatory reaction throughout the wall of the bronchus