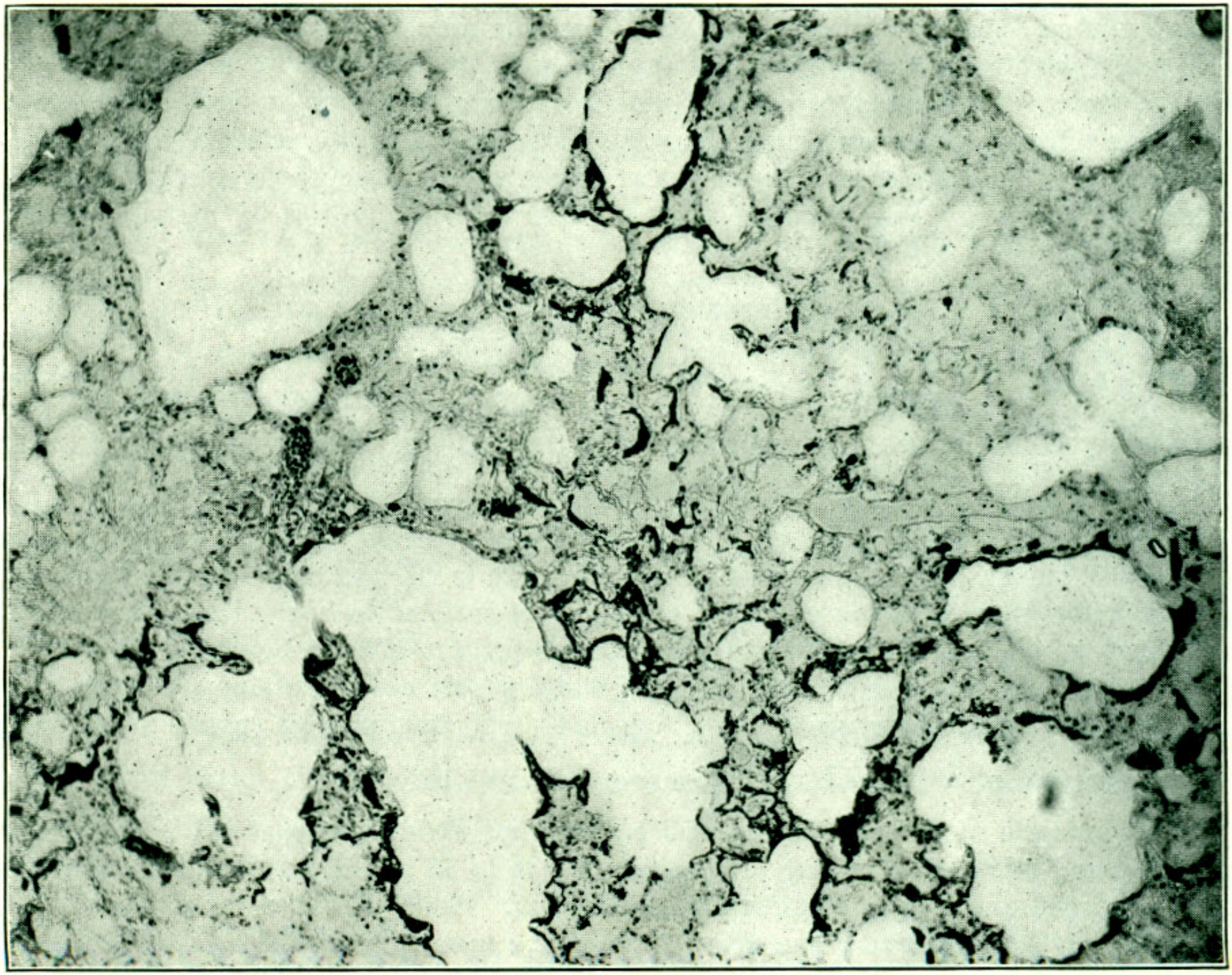

FIG. 87.—Thick layer of fibrin along the alveolar wall seven days after phosgene gassing