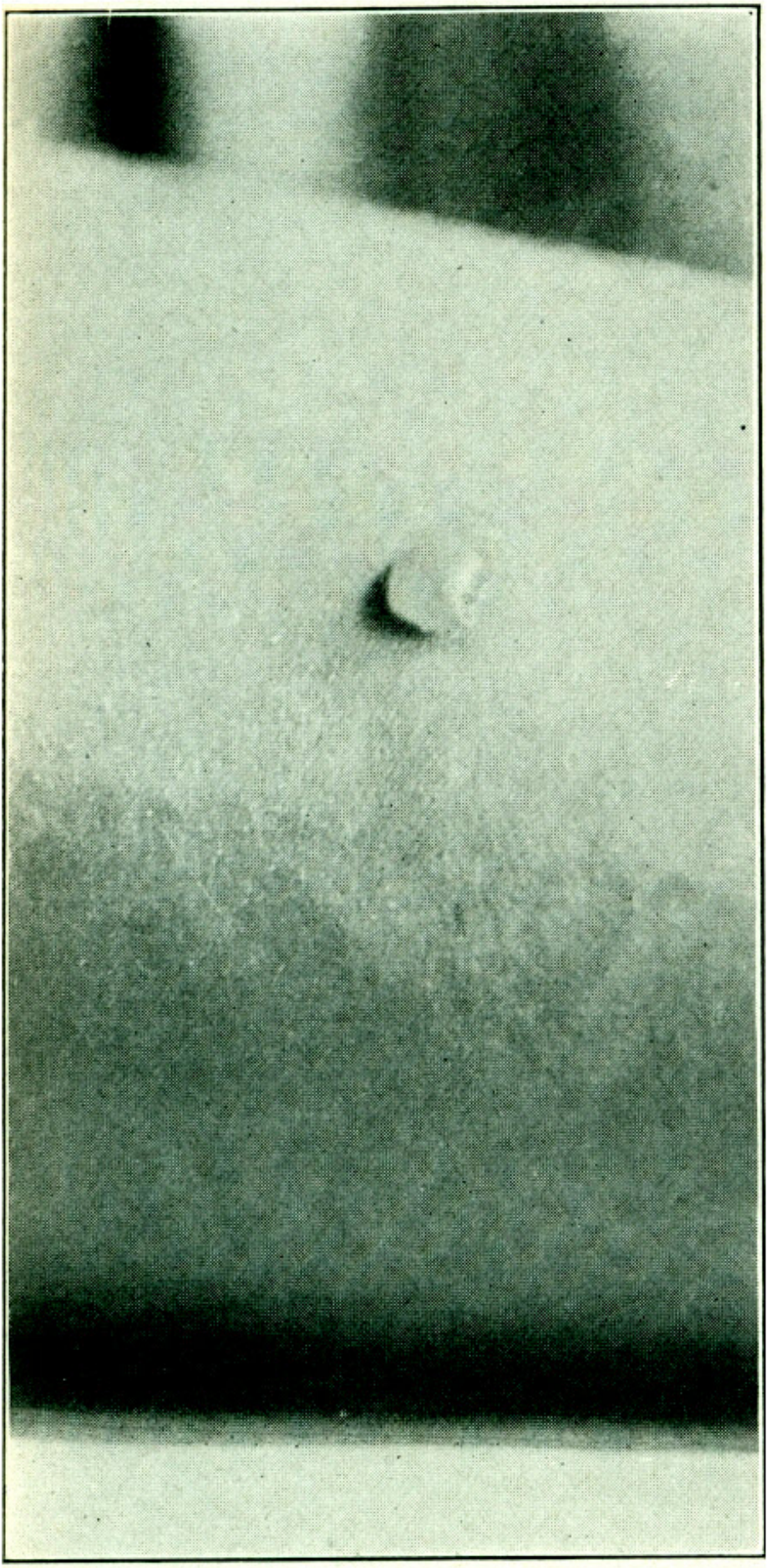

FIG. 94.—Mustard-gas lesion at 18 hours