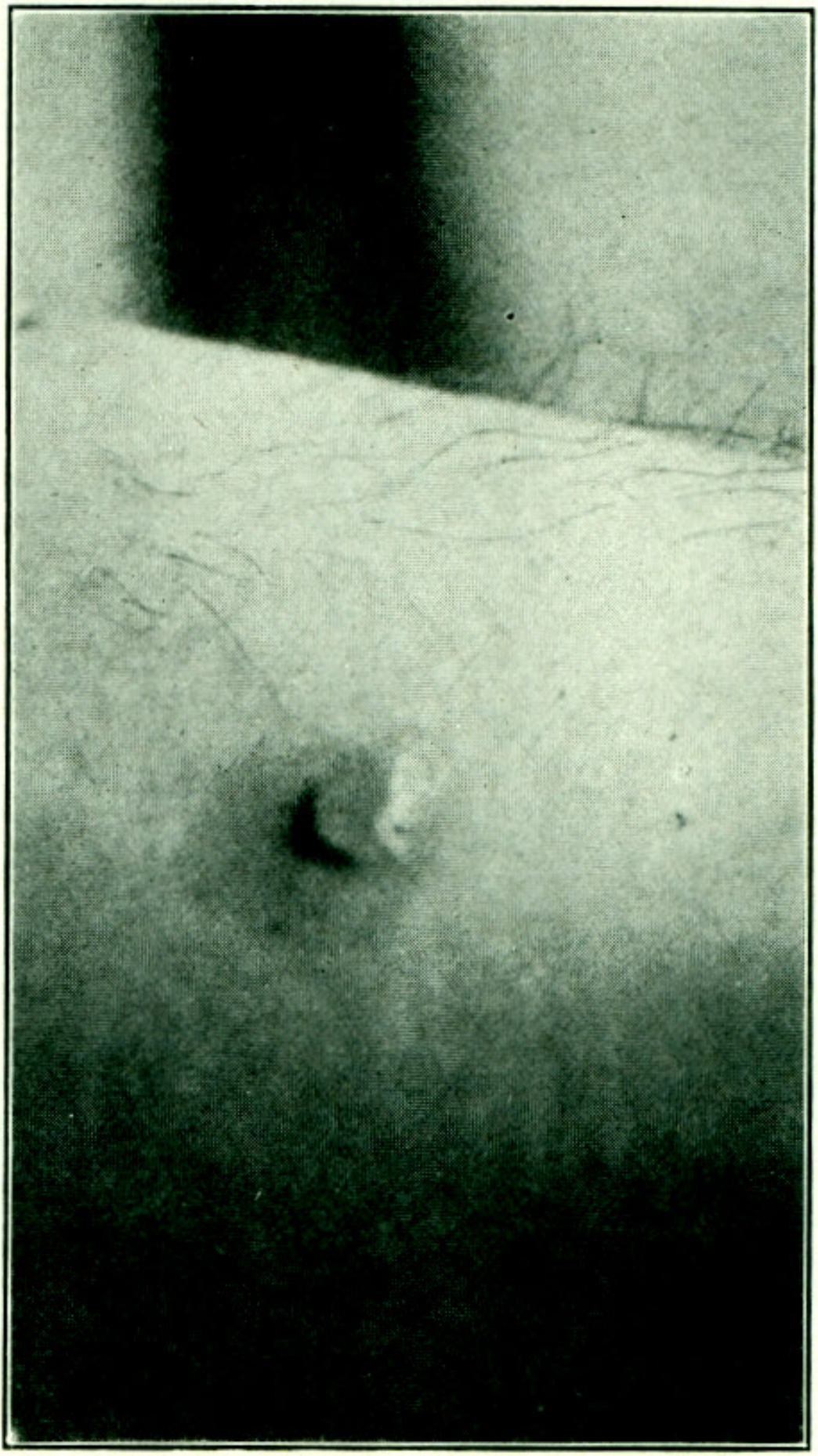

FIG. 95.—Mustard-gas lesion at 22 hours