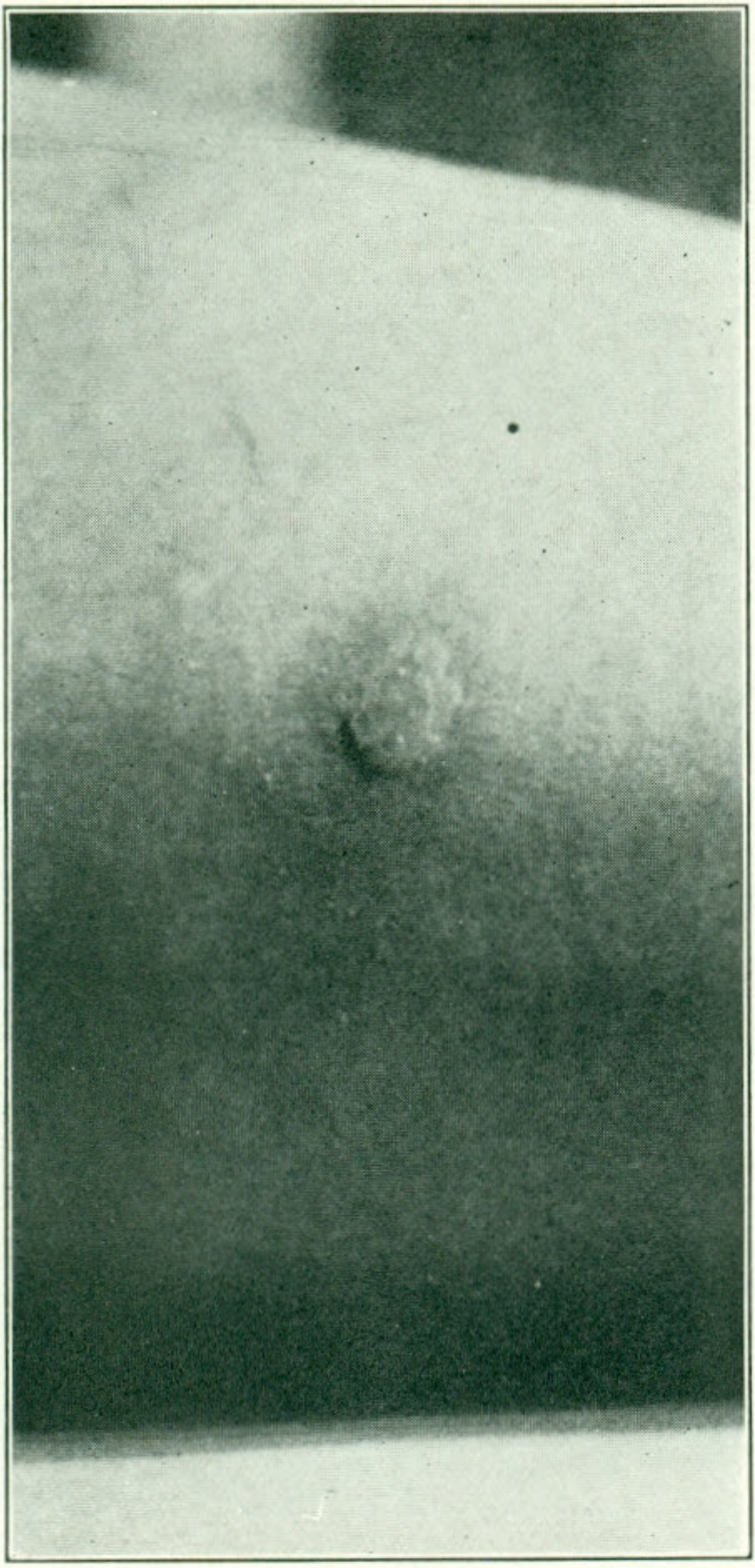

FIG. 96.—Mustard-gas lesion at 46 hours