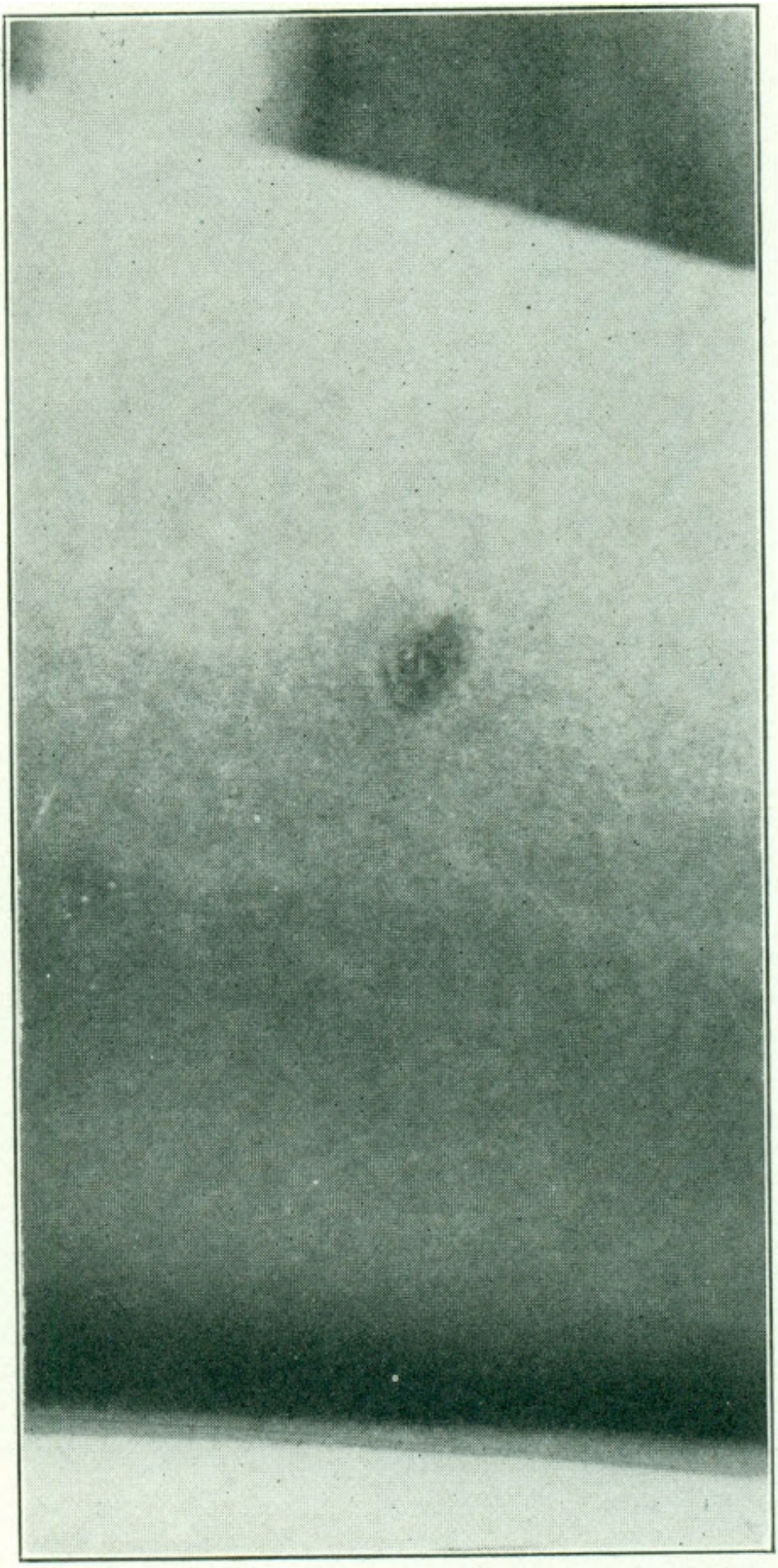

FIG. 97.—Mustard-gas lesion at 72 hours