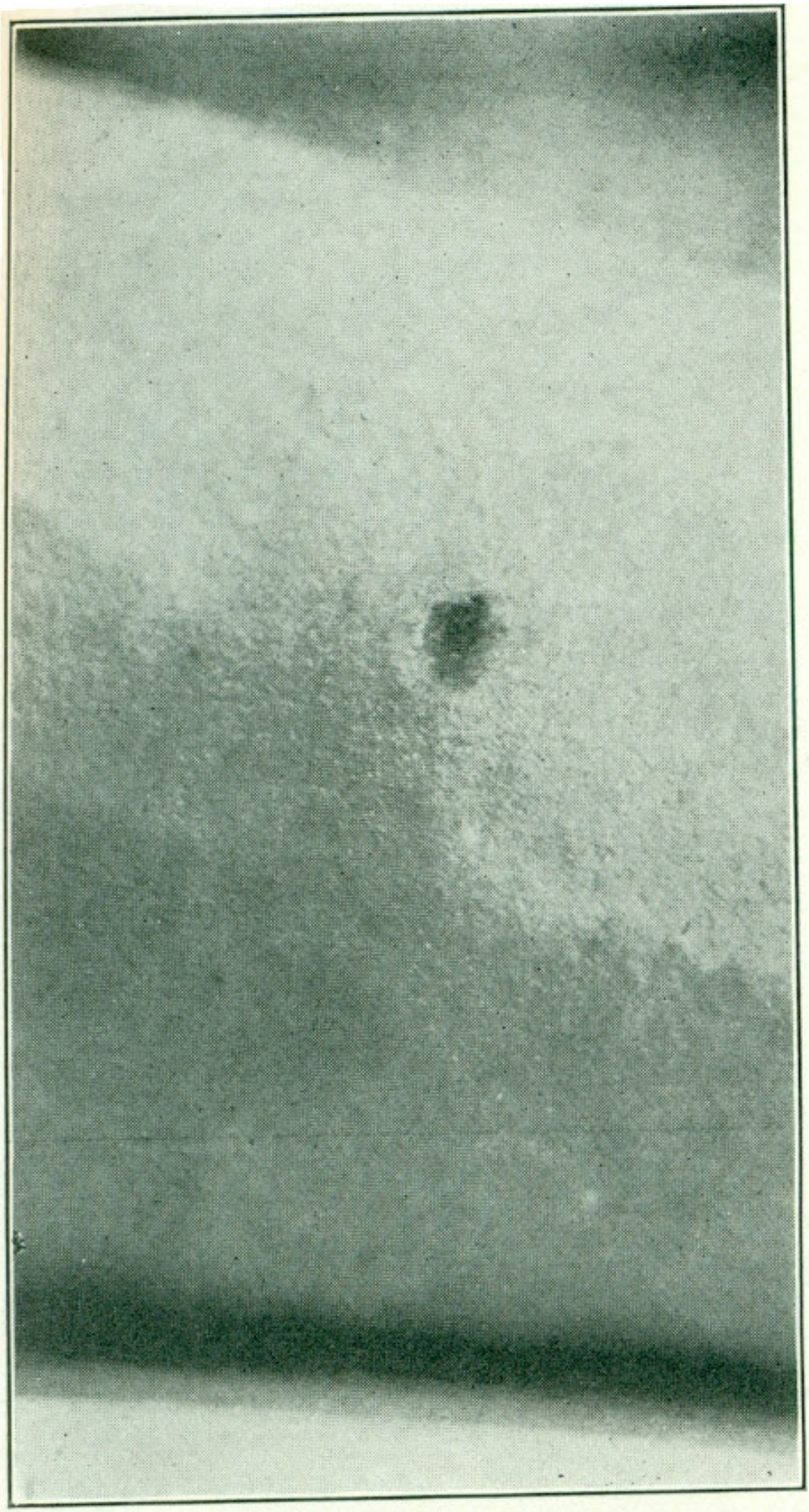

FIG. 98.—Mustard-gas lesion at four days