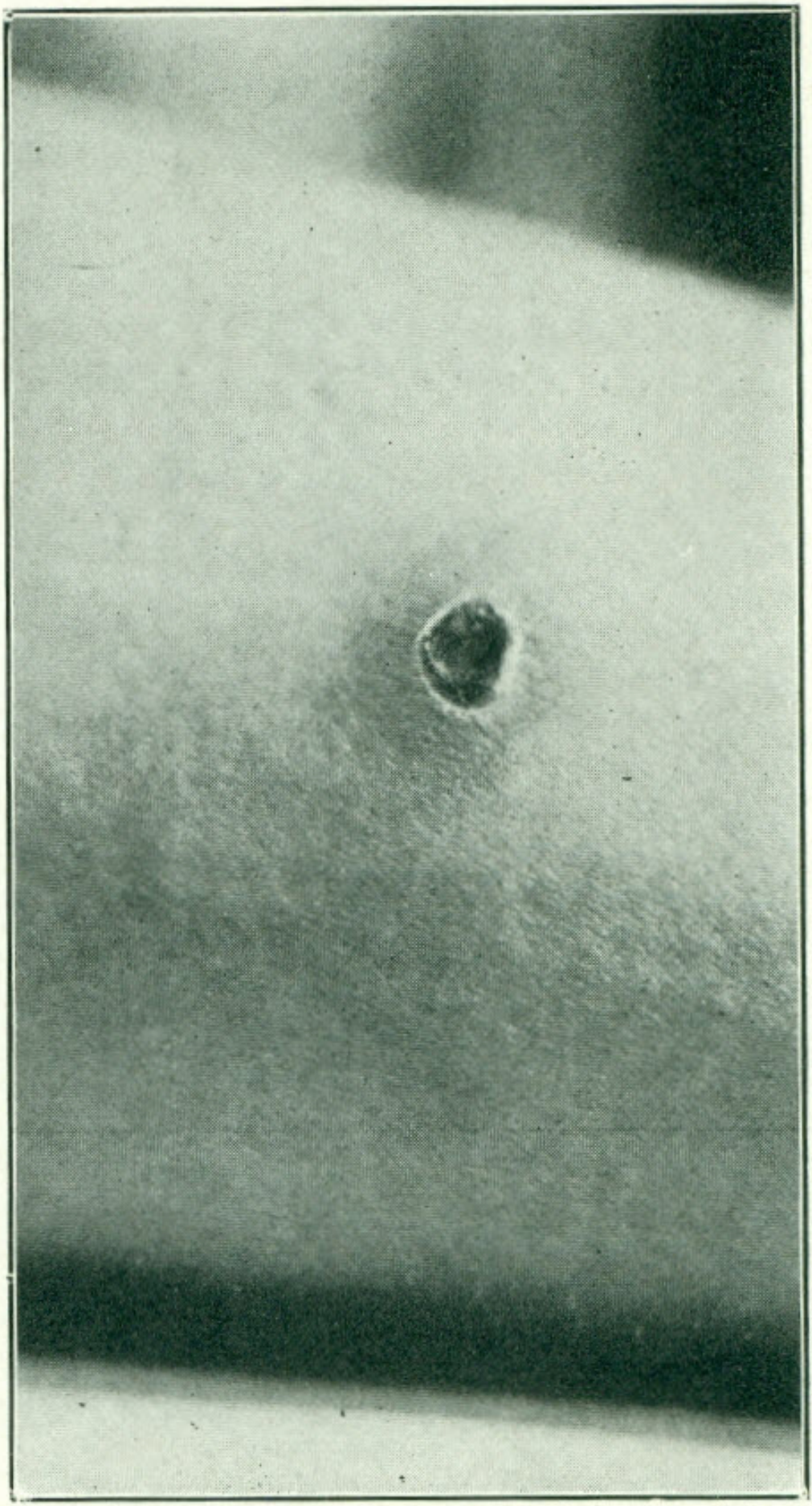

FIG. 99.—Mustard-gas lesion at nine days