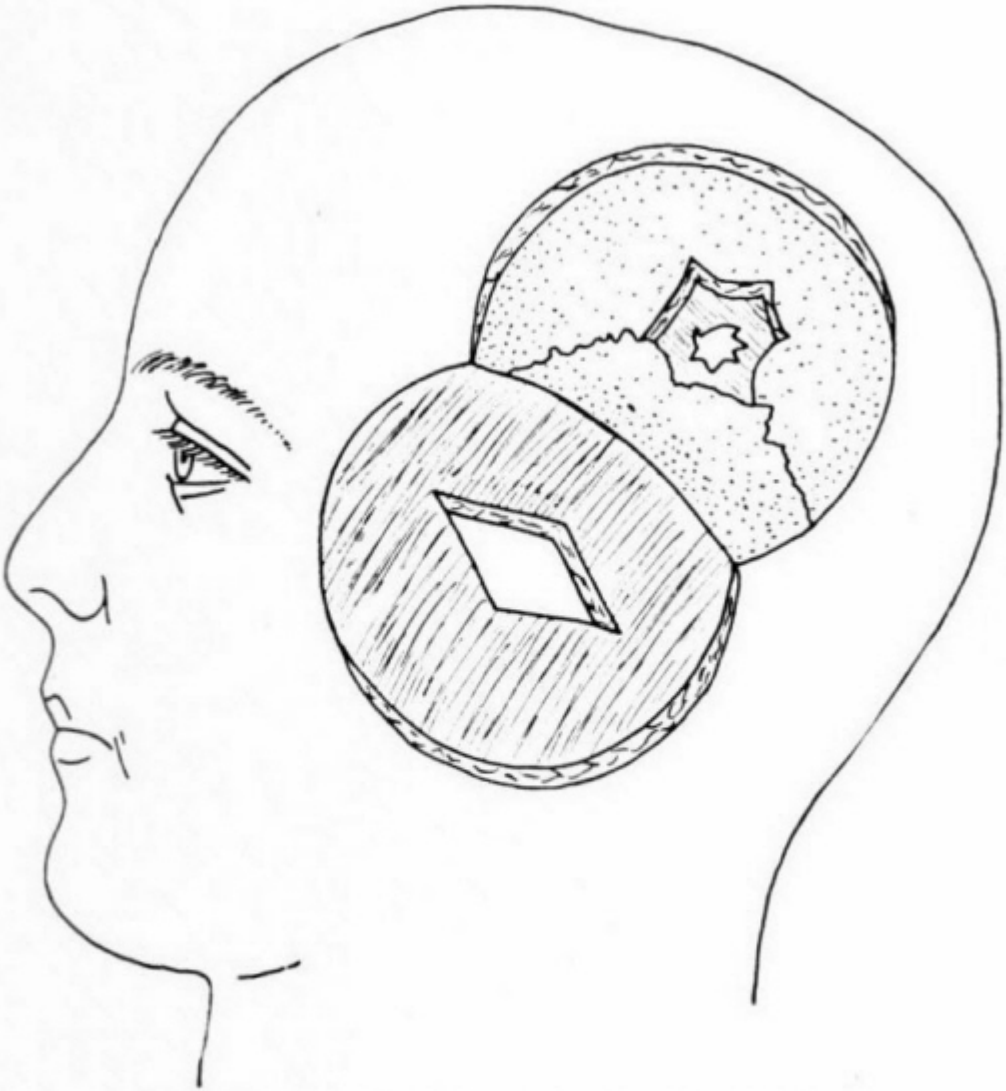

FIG. 1.—This and Figures 2 to 4, inclusive, illustrate the technique of the osteoplastic method with the wound near the center of the flap