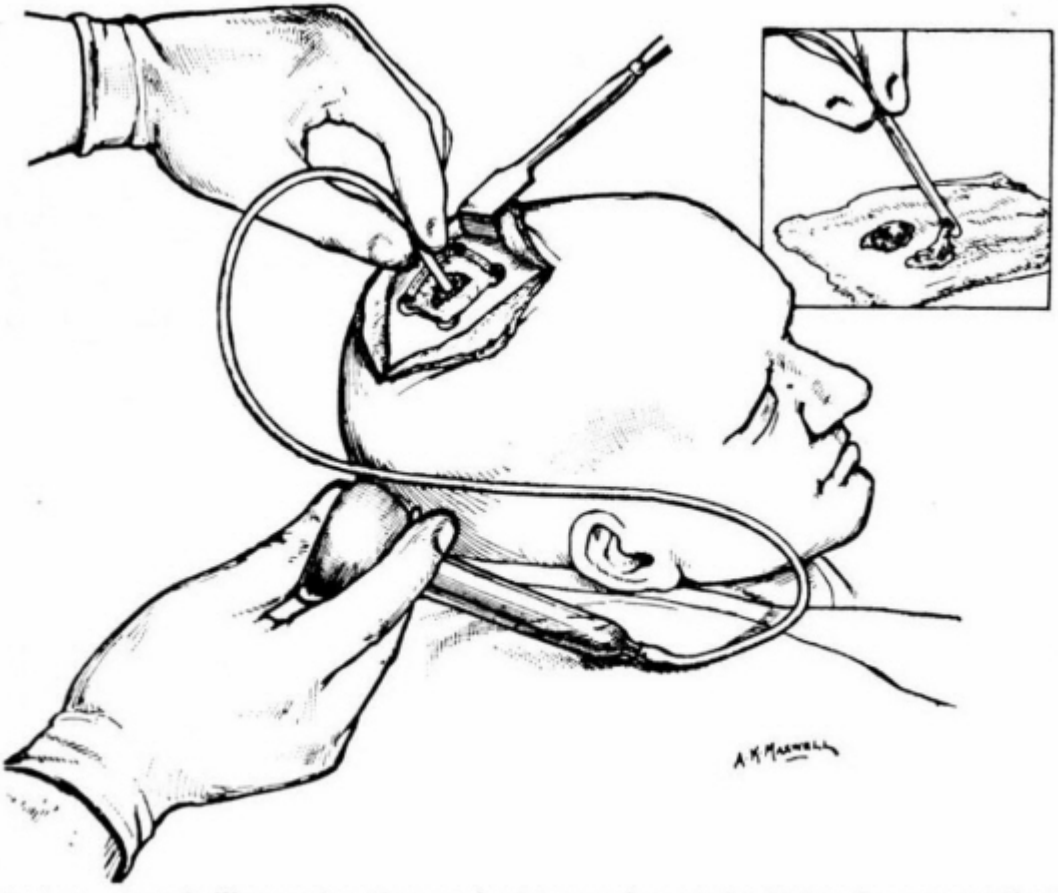

FIG. 5.—Sketch illustrating the method of suction of the tract of a penetrating wound while searching for foreign bodies