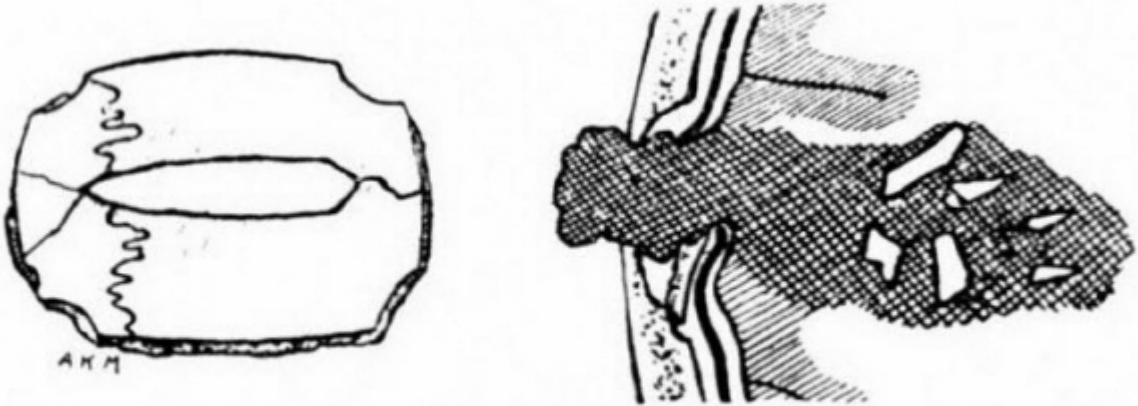

FIG. 8.—Grade IV: Wounds, usually of gutter type, with detached bone fragments driven into brain