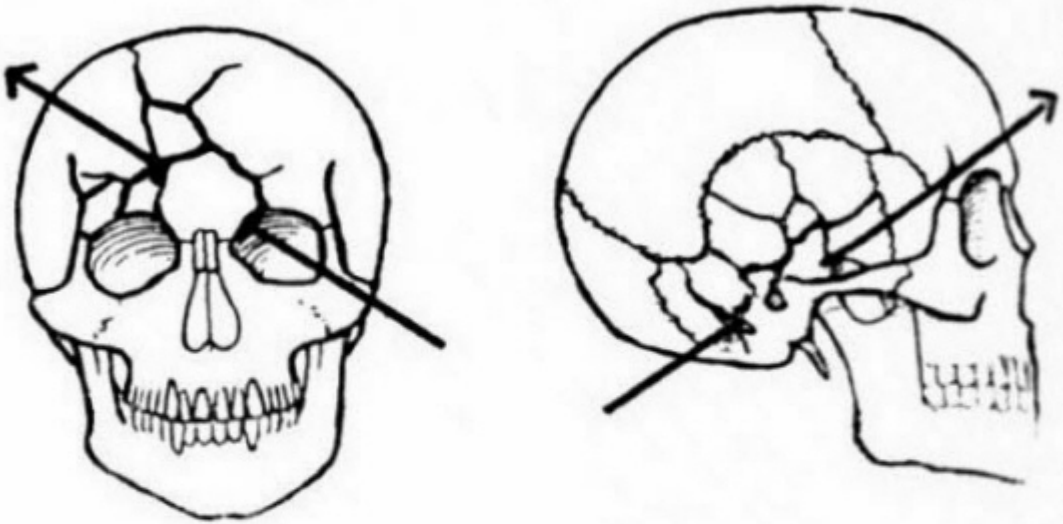

FIG. 11.—Grade VII: Wounds of craniocerebral type involving (*a*) orbitonasal, (*b*) auripetrosal region