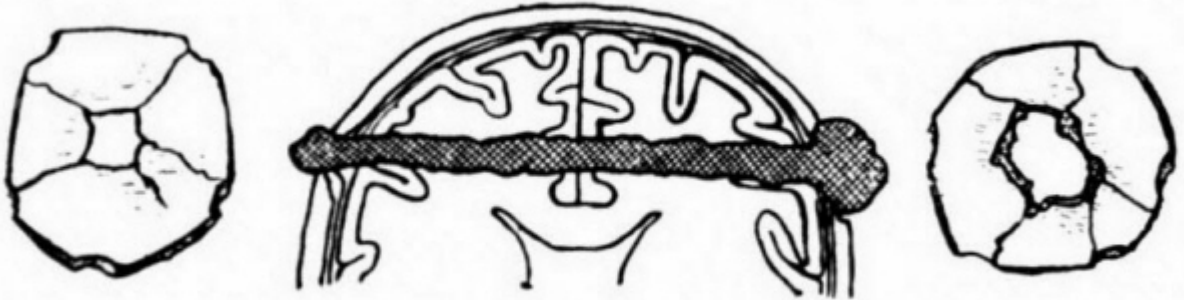

FIG. 12.—Grade VIII: Wounds with craniocerebral perforation