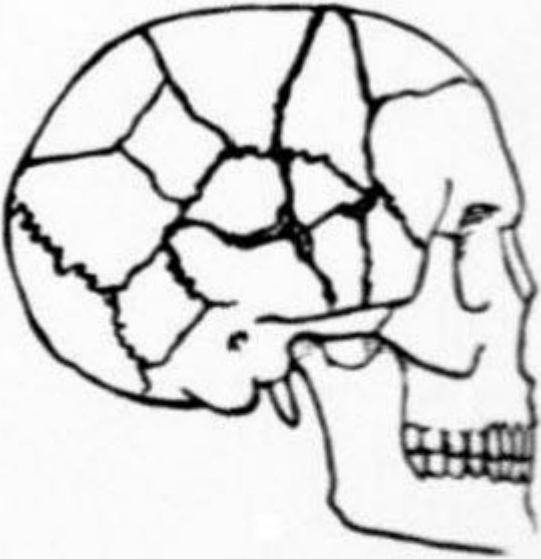

FIG. 13.—Grade IX: Craniocerebral injuries with massive fracture of skull