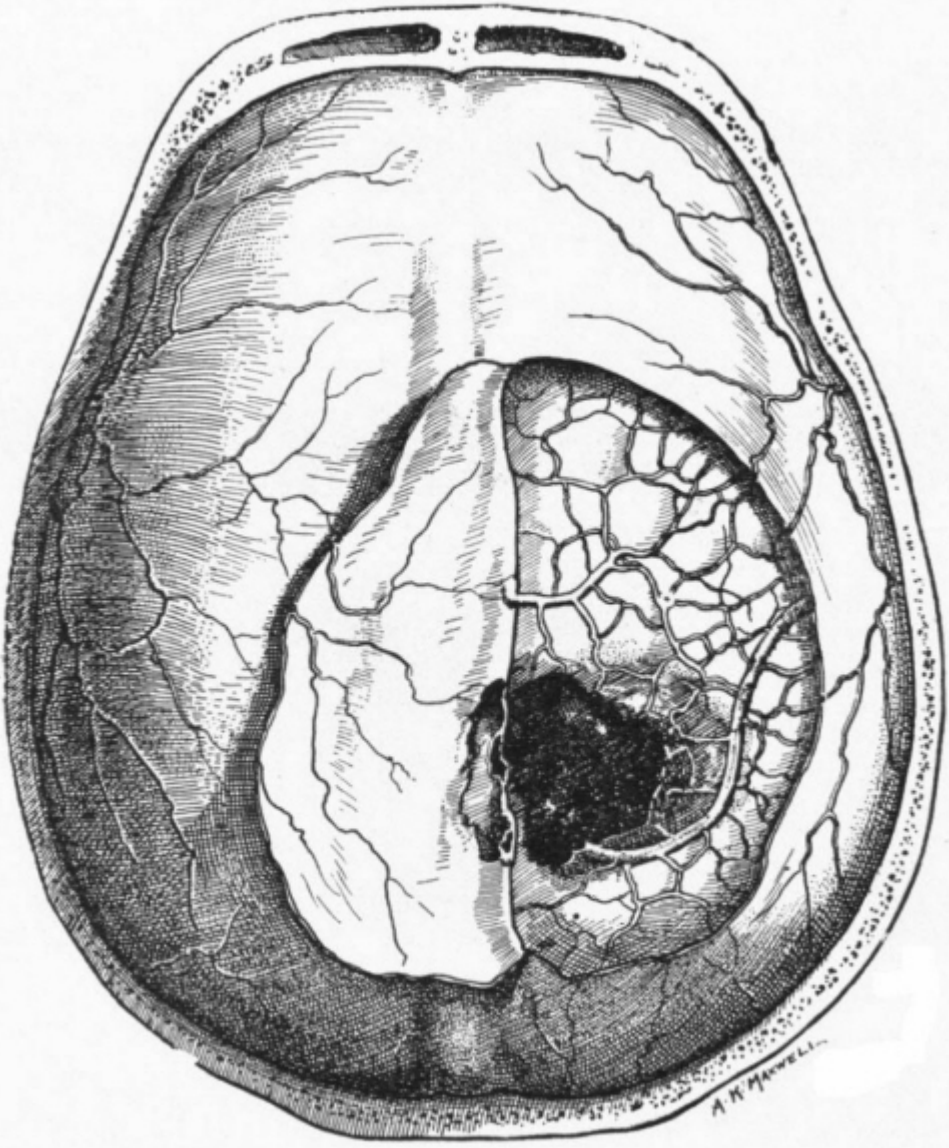

FIG. 15.—From a sketch at autopsy after removing calvarium