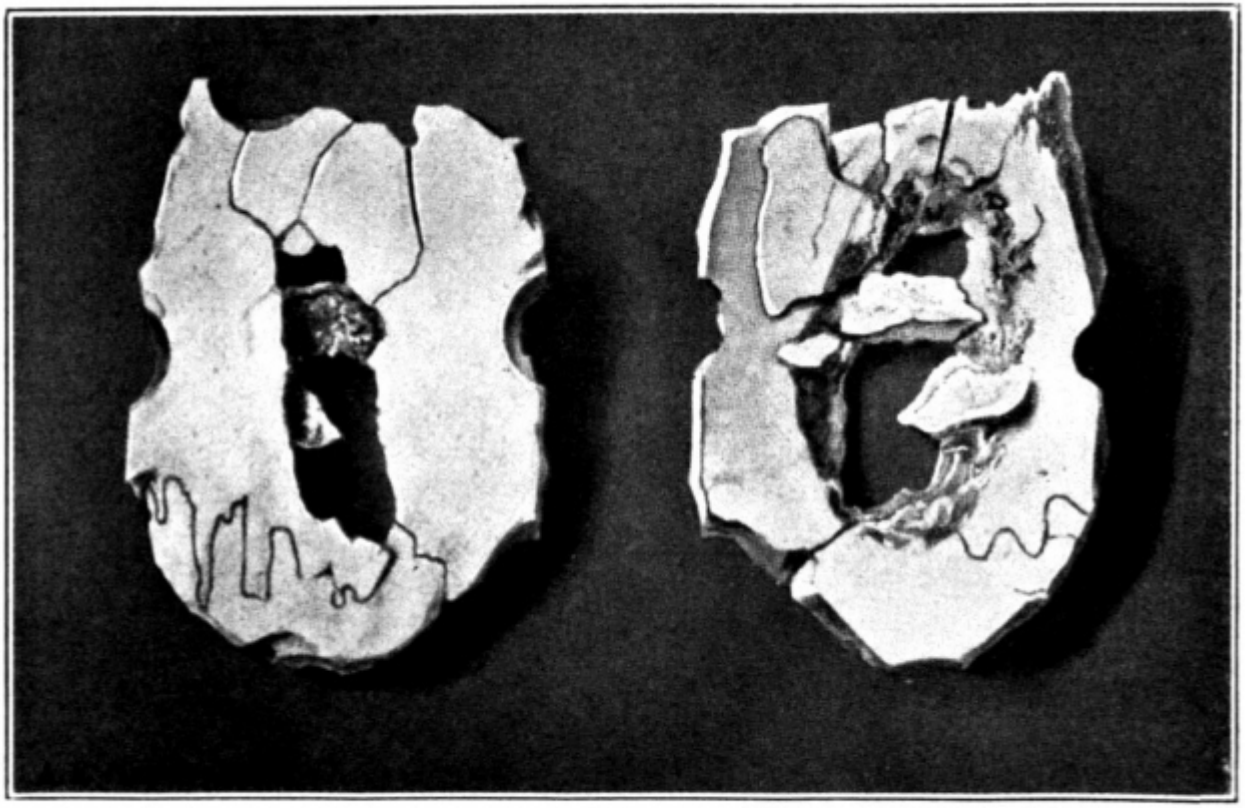

FIG. 18.—Bone block. Specimen on left shows interparietal suture and fissures radiating from gutter; on the right, a few fragments of internal table attached