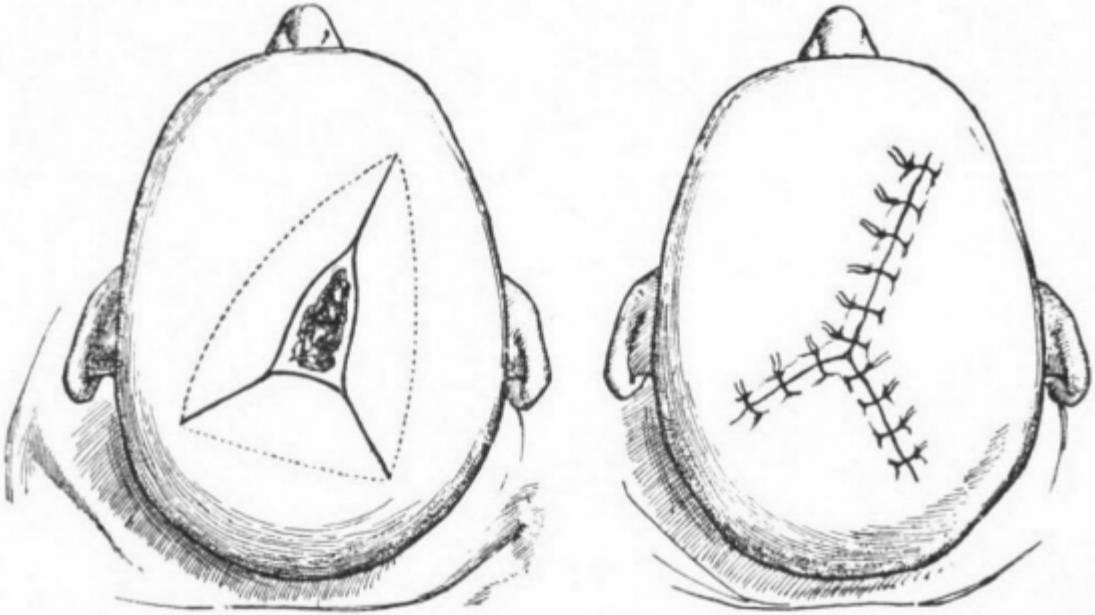

FIG. 21.—Tripod incision for small irregular wound of vault. Dotted lines indicate area of reflection of flaps. (Cushing)