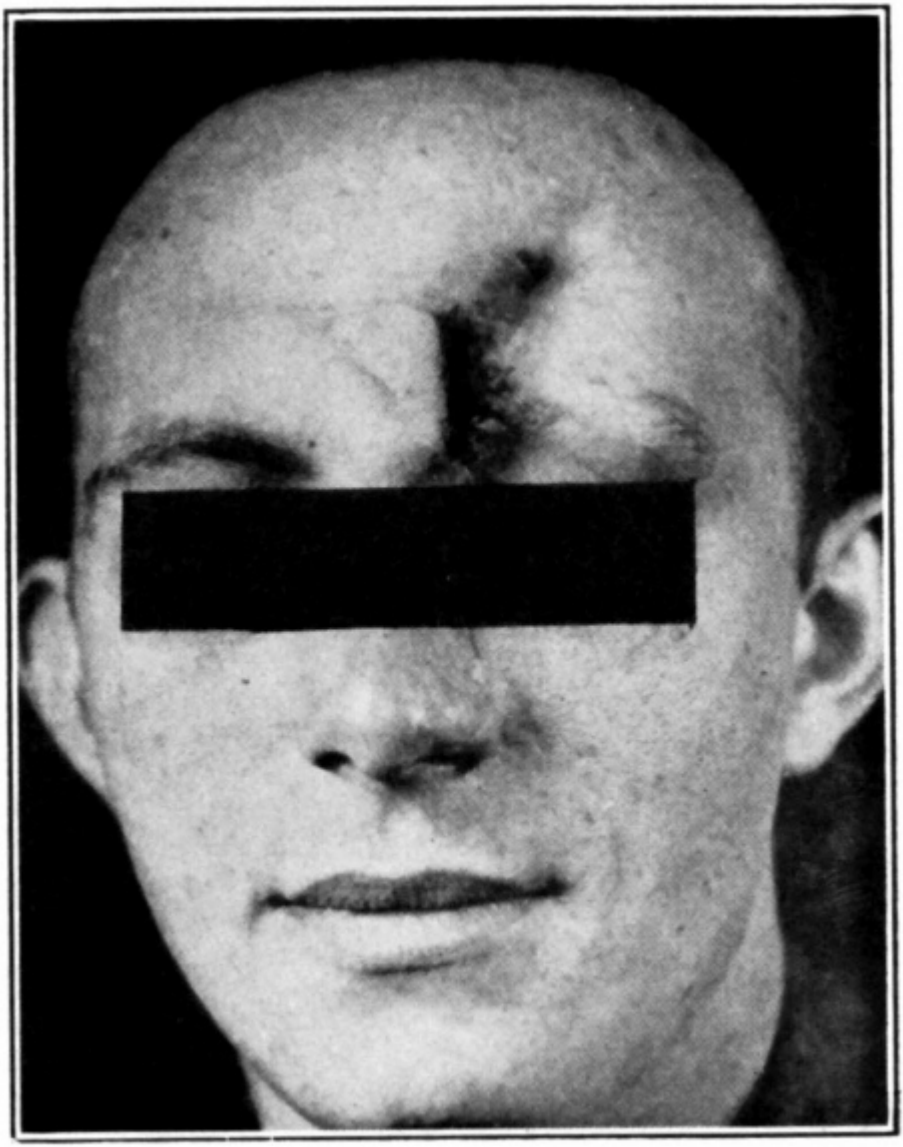

FIG. 33.—Characteristic defect in the frontal region