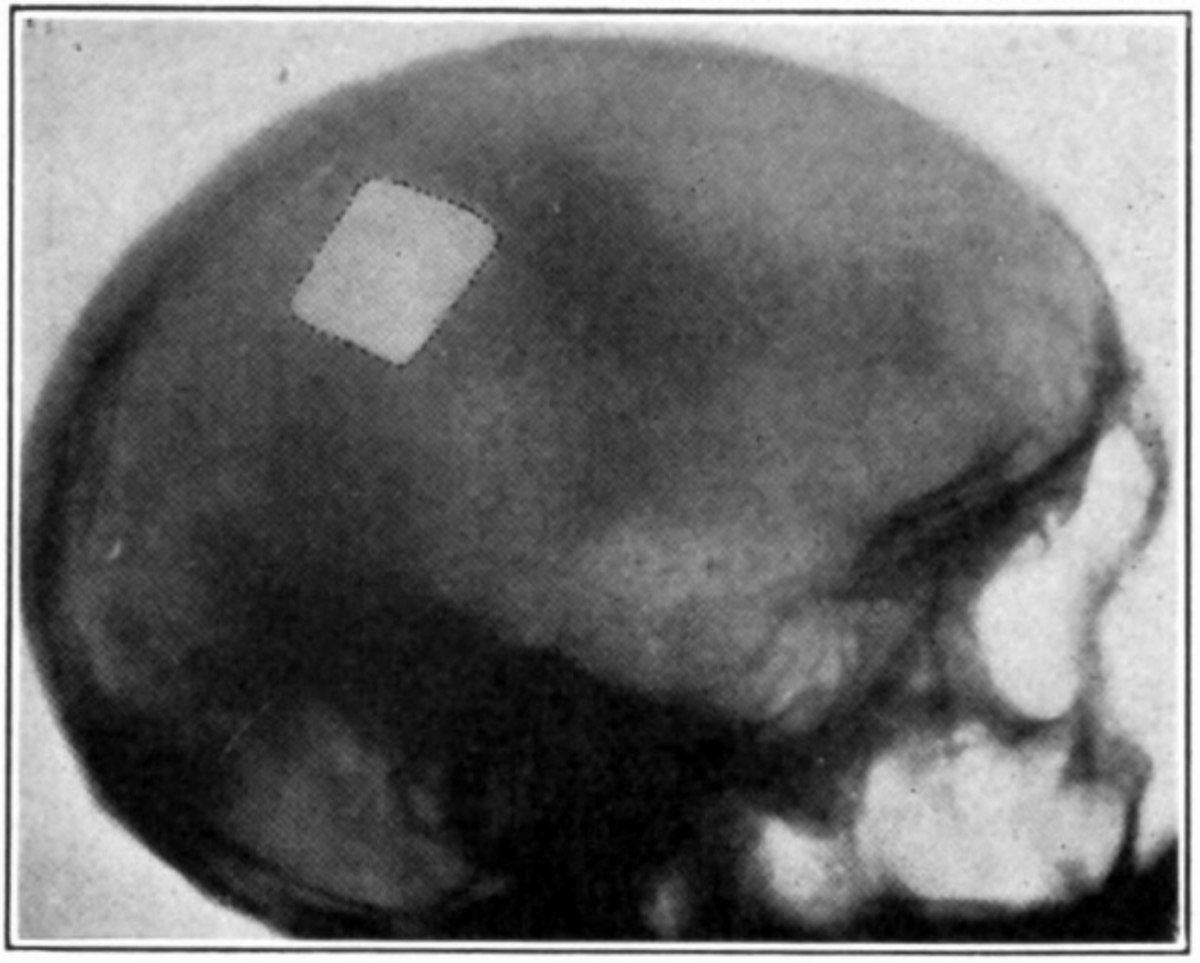

FIG. 36.—Skiagraph of a rectangular defect, in the parieto-occipital region, resulting from removal en bloc of area of skull in débridement